

## Effects of a Topically Applied Bioadhesive Berry Gel on Loss of Heterozygosity Indices in Premalignant Oral Lesions

Brian S. Shumway,<sup>1</sup> Laura A. Kresty,<sup>3,4</sup> Peter E. Larsen,<sup>1</sup> Jared C. Zwick,<sup>2</sup> Bo Lu,<sup>5</sup> Henry W. Fields,<sup>2</sup> Russell J. Mumper,<sup>6</sup> Gary D. Stoner,<sup>3,4</sup> and Susan R. Mallery<sup>1,3</sup>

**Abstract Purpose:** The aim of this study was to assess the effects of topical application of a 10% (w/w) freeze-dried black raspberry (FBR) gel on oral intraepithelial neoplasia (IEN) variables that included histologic diagnoses and loss of heterozygosity (LOH) indices. Microsatellite instability and/or LOH at tumor suppressor gene – associated chromosomal loci have been associated with a higher risk for oral IEN progression to oral squamous cell carcinoma. Previously, our laboratories have shown that FBRs are well tolerated and possess potent antioxidant, apoptotic, and differentiation-inducing properties.

**Experimental Design:** Each participant with IEN served as their own internal control. Before treatment, all lesions were photographed, and lesional tissue was hemisected to obtain a pretreatment diagnosis and baseline biochemical and molecular variables. Gel dosing (0.5 g applied four times daily for 6 weeks) was initiated 1 week after the initial biopsy. Genomic DNA was isolated from laser-captured basilar and suprabasilar surface epithelial cells followed by PCR amplification using primer sets that targeted known and presumed tumor suppressor gene loci associated with *INK4a/ARF*, *p53*, and *FHIT*. Allelic imbalance was determined by sequence analysis using normal participant tissues to establish microsatellite marker peak patterns and allele sizes.

**Results:** Confirming earlier phase I data, none of the 27 participants developed FBR gel – associated toxicities. Furthermore, our results show histologic regression in a subset of patients as well as statistically significant reduction in LOH at tumor suppressor gene – associated loci.

**Conclusions:** These preliminary data suggest that further evaluation of berry gels for oral IEN chemoprevention is warranted.

Oral squamous cell carcinoma (SCC) is associated with significant morbidity, mortality, and an economic cost that rivals or exceeds other solid tumors (1–3). Oral premalignant lesions [oral intraepithelial neoplasia (IEN)], histopathologically described as grades of oral epithelial dysplasia, arise as clinically detectable red and white patches in the mouth before the development of overt oral SCC (4). Clinical assessment for

an 8-year period revealed that up to 36% of oral IEN lesions may progress to SCC (5, 6). Although the more advanced premalignant lesions are usually completely excised, recurrences of lesional tissue (7) or development of new premalignant lesions is not uncommon (8, 9). Repeated surgical procedures are expensive, increase morbidity, and complicate subsequent clinical evaluations due to postsurgical scarring.

Chemoprevention, which entails the prevention, inhibition, or reversal of malignant transformation by intervention with chemically derived or naturally occurring dietary substances, is a potential treatment alternative to, or adjunct for, surgery (10). As opposed to surgical ablative or cytotoxic treatments, which destroy both normal and abnormal cells, chemopreventive approaches are potentially more lesional cell specific. Black raspberries are one natural food product that has shown significant chemopreventive promise (11–21). Furthermore, the removal of water by freeze drying concentrates the bioactive constituents of black raspberries ~10-fold relative to the natural fruit (19). Freeze-dried black raspberries (FBR) contain appreciable quantities of many putative chemopreventive compounds, including vitamins A, C, and E, folic acid, selenium,  $\alpha$  and  $\beta$  carotene, ellagic acid, ferulic acid, coumaric acid, and quercetin, in addition to multiple anthocyanins and phytoosterols (12, 16). Although all of the chemopreventive mechanisms of action of FBR have not been elucidated, our results show the capacities of FBR to suppress redox-mediated intracellular signaling (13), inhibit survival pathways in transformed cells (11), reduce production of proangiogenic

**Authors' Affiliations:** <sup>1</sup>Department of Oral and Maxillofacial Surgery, Anesthesiology and Pathology, College of Dentistry, <sup>2</sup>Department of Orthodontics, College of Dentistry, <sup>3</sup>Comprehensive Cancer Center and Solove Research Institute, <sup>4</sup>Department of Internal Medicine, College of Medicine, and <sup>5</sup>Division of Biostatistics, College of Public Health, The Ohio State University, Columbus, Ohio and <sup>6</sup>Division of Molecular Pharmaceutics, School of Pharmacy, University of North Carolina at Chapel Hill, Chapel Hill, North Carolina  
Received 9/4/07; revised 1/25/08; accepted 1/31/08.

**Grant support:** NIH/National Cancer Institute grant R21 CA111210 (S.R. Mallery), Ohio Division of the American Cancer Society Research Fellowship (B.S. Shumway), and U.S. Department of Agriculture 38903-03560 (G.D. Stoner).

The costs of publication of this article were defrayed in part by the payment of page charges. This article must therefore be hereby marked *advertisement* in accordance with 18 U.S.C. Section 1734 solely to indicate this fact.

**Note:** Supplementary data for this article are available at Clinical Cancer Research Online (<http://clincancerres.aacrjournals.org/>).

**Requests for reprints:** Susan R. Mallery, Department of Oral Maxillofacial Surgery and Pathology, College of Dentistry, The Ohio State University, Columbus, OH 43210-1241. Phone: 614-292-5892; Fax: 614-292-9384; E-mail: mallery.1@osu.edu.

©2008 American Association for Cancer Research.  
doi:10.1158/1078-0432.CCR-07-4096

**Table 1.** Clinical trial patient demographics, histologic diagnoses, and follow-up information

**A. Oral IEN patient demographics and histopathologic diagnoses pretreatment and posttreatment**

Patient no.	Age	Patient and lesion characteristics						Histopathologic diagnosis		
		Gender	Smoking*	Alcohol <sup>†</sup>	High-risk site <sup>‡</sup>	Multifocal <sup>§</sup>	Recurrent <sup>  </sup>	Size (cm) <sup>¶</sup>	Pretreatment diagnosis	Posttreatment diagnosis
1	74	M	Y	N	N	N	N	2.3 × 0.8	Severe dysplasia, cannot rule out superficially invasive SCC	Moderate, focally severe dysplasia
2	75	M	Y	Y	Y	Y	Y	1.8 × 0.8	Mild dysplasia	Hyperparakeratosis, atypia
3	59	M	Y	Y	N	Y	Y	1.0 × 1.0	Severe dysplasia	Moderate dysplasia
5	75	F	Y	N	N	Y	N	0.8 × 0.6	Mild dysplasia	Hyperkeratosis, atypia
6	44	M	N	Y	N	N	Y	0.6 × 0.4	Hyperkeratosis, atypia	Hyperorthokeratosis, atypia
7	58	M	N	Y	Y	N	Y	2.1 × 0.6	Moderate dysplasia	Moderate dysplasia
8	76	F	Y	Y	Y	N	N	1.2 × 0.5	Mild dysplasia	Focal carcinoma <i>in situ</i>
9	26	F	Y**	Y	N	Y	Y	0.3 × 0.3	Hyperkeratosis, atypia	Hyperkeratosis
10	66	M	Y	N	Y	N	N	2.2 × 1.2	Moderate dysplasia	Hyperparakeratosis, atypia
11	59	F	Y	N	N	Y	N	2.0 × 1.0	Hyperkeratosis, atypia	Mild dysplasia
12	56	F	N	N	N	Y	N	1.2 × 1.0	Hyperkeratosis, atypia	Hyperkeratosis, atypia
13	59	F	N	Y	Y	N	Y	2.2 × 0.6	Hyperkeratosis, atypia	Hyperkeratosis, atypia
14	44	F	N	Y	Y	Y	Y	2.2 × 0.8	Severe dysplasia	Moderate dysplasia
15	43	M	Y	N	N	Y	N	1.2 × 0.5	Hyperkeratosis, atypia	Hyperkeratosis, atypia
17	55	F	Y**	Y	N	Y	Y	0.8 × 0.4	Mild dysplasia	Moderate dysplasia
18	73	F	Y	N	Y	Y	N	2.0 × 1.0	Focal moderate dysplasia	Moderate dysplasia
19	64	F	Y	Y	Y	N	Y	2.5 × 1.5	Focal moderate dysplasia	Focal severe dysplasia
<b>Range</b>		<b>Totals</b>	<b>Totals</b>	<b>Totals</b>	<b>Totals</b>	<b>Totals</b>	<b>Totals</b>		<b>Histopathologic change</b>	
26-76		M = 7	Y = 12	Y = 10	Y = 8	Y = 10	Y = 9		Decrease in grade = 7	
<b>Mean</b>		F = 10	N = 5	N = 7	N = 9	N = 7	N = 8		Increase in grade = 4	
59.2									Stable disease = 6	

\*Y, history of smoking; N, no history of smoking.

<sup>†</sup>Y, current alcohol use; N, no alcohol use.

<sup>‡</sup>Y, lesion location at high risk for progression to SCC (lateroventral tongue, floor of mouth, and tonsillar pillar); N, lesion location at lower risk for progression to SCC (buccal mucosa, gingival, and hard/soft palate).

<sup>§</sup>Y, multiple IEN lesions observed clinically; N, isolated clinical disease.

<sup>||</sup>Y, selected site represents recurrent disease; N, selected site presents new disease.

<sup>¶</sup>Size of oral IEN lesion before treatment.

\*\* Indicates quit smoking ≤1 y ago.

<sup>††</sup> For recurrent lesions, the diagnosis at follow-up is listed succeeded by posttreatment diagnosis in parentheses as previously listed in Table 1A.

<sup>‡‡</sup> No recurrent lesional tissue was identified clinically.

cytokines (14, 17), and stimulate apoptotic and terminal differentiation pathways (14). *In vivo*, dietary administered FBR suppressed carcinogenesis in both hamster cheek pouch (15) and rat esophageal cancer models (16–18), inhibited expression of pro-proliferative and inflammatory enzymes (18), and suppressed tumor-associated angiogenesis (17). In addition, phase I human clinical trials have shown that orally

administered FBR were well tolerated (19–21) and also showed the potential for FBR metabolism following oral administration by the detection of berry metabolites in the urine (21). Recently, our laboratories developed and characterized a bioadhesive berry gel for application to the human oral mucosa (22). Aspects of this gel, which include an anthocyanin stabilizing pH (pH 3.5), mucosal bioadhesive and penetrative

**Table 1.** Clinical trial patient demographics, histologic diagnoses, and follow-up information (Cont'd)

<b>B. Clinical trial disease status follow-up information</b>			
<b>Patient no.</b>	<b>Follow-up (mo)</b>	<b>Treatment site<sup>††</sup></b>	<b>Other oral sites</b>
1	7	Progression to well-differentiated SCC (moderate, focally severe dysplasia)	No other lesions observed
2	5	Mild dysplasia (atypia)	Mild dysplasia at one new site
3	13	Moderate dysplasia (moderate dysplasia)	Developed verrucous carcinoma at 2 sites
5	18	No recurrence <sup>††</sup>	Atypia at one new site
7	20	Moderate dysplasia (moderate dysplasia)	No other lesions observed
9	15	No recurrence <sup>††</sup>	Atypia at one new site
10	16	Mild dysplasia (atypia)	No other lesions observed
14	10	Severe dysplasia (moderate dysplasia)	Atypia at one new site
15	3	No recurrence <sup>††</sup>	Atypia at several new sites
19	3	Moderate to severe dysplasia (focally severe dysplasia)	Moderate dysplasia at one new site

properties, and capacity for local agent delivery, make this a suitable preparation for evaluation of FBR chemopreventive effects in oral IEN lesions.

Previous oropharyngeal chemopreventive trials have used a variety of orally administered agents, with a heavy reliance on retinoic acid derivatives (23, 24). Although retinoids and their synthetic retinamide derivatives induced regression of oral IEN lesions, these agents were also associated with significant toxicities, such as cheilitis, skin dryness, hypertriglyceridemia, and mucositis (25–27). In addition, oral cavity-pharyngeal tissue site-specific differences in chemopreventive responsiveness were noted. Oral cavity lesions were particularly difficult to manage and often showed resistance to multiagent treatment protocols (26–28). Recently, a mouthwash containing an adenovirus vector that targeted epithelial cells with defective p53 signaling was clinically evaluated (29). Although this mouthwash induced histologic regression in 37% of participants, lesions often recurred after cessation of therapy and one participant developed antibody titers to the adenovirus vector (29).

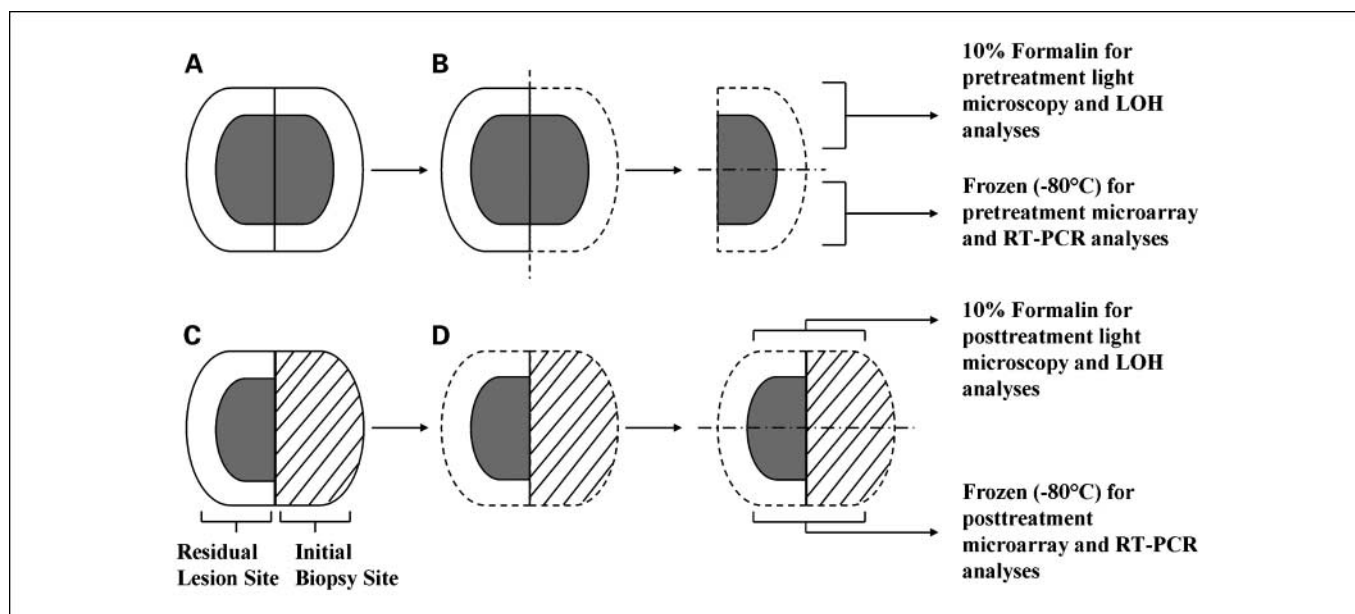
Although there is currently no consensus about what comprises the ideal clinical trial biomarker(s), it is generally agreed that the selected indicators should predict the risk of cancer development. Silencing of tumor suppressor genes, either by mutation, promoter methylation, microsatellite instability, or loss of heterozygosity (LOH), is associated with development of many human cancers, including oral SCC (30–32). Consequently, monitoring LOH indices at critical chromosomal loci associated with tumor suppressor genes [3p14 (*FHIT*), 9p21 (*INK4a/ARF*), and 17p13 (*p53*)] is a rational approach to assess chemopreventive efficacy. To date, only a single trial has evaluated pretreatment and posttreatment chemopreventive effects on LOH indices in oral and laryngeal IEN lesions (33). This trial entailed a combination of oral delivery of 13-*cis*-retinoic acid and  $\alpha$ -tocopherol in conjunction with s.c. administration of IFN $\alpha$  (33). Complete clinical and histologic resolution was observed in five of nine lesions (33). Despite these impressive clinical effects, eight of nine patients retained LOH at 9p21, implying that potentially significant molecular perturbations remained at the treatment sites (33).

Based on our preclinical black raspberry studies, we hypothesized that the FBR gel would be clinically active in oral IEN lesions due to its abilities to induce apoptotic and/or terminal differentiation pathways, resulting in elimination of premalignant clones in the lesional epithelium. Accordingly, the purpose of this study was to evaluate the effects of topical application of a 10% (w/w) FBR bioadhesive gel on oral IEN variables that included light microscopic diagnoses and LOH indices. Our data show that berry gel topical application (0.5 g applied four times daily for 6 weeks) is well tolerated and significantly reduces LOH indices at chromosomal loci associated with tumor suppressor genes in human oral IEN lesions.

## Materials and Methods

**Berry gel manufacturing.** The bioadhesive gels used in this clinical trial were prepared using current Good Manufacturing Practices at the Center for Pharmaceutical Science and Technology at the University of Kentucky (Lexington, KY). A description of the quality control measures and details of the gel composition and method of manufacture have been described previously (22). Briefly, the gel composition used for the clinical trial consisted of the following (% w/w): Noveon AA1 (NF; Noveon, Inc.), 1.35; Carbopol 971P (NF; BF Goodrich Specialty Chemicals), 1.575; glycerin (USP), 1.0; edentate disodium (USP), 0.1; 2-phenoxyethanol (BP), 1.0; benzyl alcohol (USP), 1.0; FBR, 10; and purified water Qs to 100 (22). Based on our previous stability and mucosal penetration data (22), slight modifications of the prototype gel were made for the clinical trial gel. The FBR concentration was increased to 10% (w/w) and the pH of the gel was fixed at pH 3.5 to stabilize the more biologically active flavylium cation of the anthocyanin molecules.

**Human clinical trial.** Twenty-nine adults (age range, 18–76 y) were consented to participate in our clinical trial, which received approval from The Ohio State University Institutional Review Board (protocol 2003C0050). Nineteen had clinical lesions suggestive of IEN, of which two patients (#4 and #16) did not participate because they did not meet the histopathologic eligibility criteria for treatment. Criteria for inclusion as IEN participants were microscopically confirmed premalignant oral epithelial changes (noninvasive disease) and no use of tobacco products for 6 wk before, and for the duration of, the clinical trial. Study exclusion criteria included use of tobacco products within 6 wk before or during the clinical trial, or a microscopic diagnosis of invasive oral SCC. Seventeen participants had oral lesions that were



**Fig. 1.** Oral IEN tissue biopsy protocol. ■, dysplastic lesion; □, adjacent normal mucosa; ▨, healing mucosa; - - -, biopsy incision; —■—, tissue sectioning. **A**, pretreatment dysplastic lesion with adjacent normal mucosa. **B**, pretreatment hemisection with removal of half of the lesion with additional tissue sectioning for baseline analyses. **C**, residual dysplastic lesion and healing biopsy site treated with FBR gel for 6 wk. **D**, posttreatment excision of remaining dysplastic lesion and healed mucosa with tissue sectioning for final analyses. By creating a wound, this protocol activated the epithelial transient amplifying and stem cell pools. RT-PCR, reverse transcription-PCR.

clinically consistent with, and microscopically confirmed, as premalignant oral lesions (histopathologic diagnoses ranged from epithelial atypia to severe dysplasia; see Table 1A). The site, size, and consistency of premalignant lesions were recorded and clinical photographs were obtained.

The remaining 10 individuals (5 men and 5 women; ages between 24 and 34 y) exhibited clinically healthy, normal oral mucosa and participated in the clinical trial for the following reasons: (a) to allow additional observations for treatment-associated side effects, (b) to evaluate the clinical and histopathologic effects of berry gel application on normal oral mucosa, and (c) to provide additional treated tissue for establishing peak patterns and allele sizes during microsatellite analyses. Importantly, these subjects did not serve as a true "control" group in that direct comparison of treatment effects with IEN patients was not intended. Their treatment protocol was identical to the IEN patients except that only a posttreatment biopsy was taken to reduce morbidity. Seven of these 10 normal participants had never used tobacco products or consumed alcohol. The remaining three normal participants reported negligible (one participant) and modest alcohol (two participants) consumption with no use of tobacco products.

At the initial treatment appointment, half of the lesional tissue was excised, a portion was placed in 10% neutral buffered formalin for histopathologic diagnosis and LOH studies, and a portion was immediately frozen for microarray and reverse transcription-PCR analyses (reported in a separate publication; see Fig. 1). This approach, which ensured that pretreatment indices for each variable to be evaluated were obtained, enabled each participant with IEN to serve as their own internal control. Further, the wound introduced by the incisional biopsy activated the optimal chemoprevention cell target (i.e., the transient amplifying and stem cell pools). To maximize the benefits of local delivery, our protocol entailed multiple dosing throughout the day (0.5 g applied four times daily for 6 wk). The human oral epithelium regenerates approximately every 28 d. As the ventrolateral tongue is a high incidence site for oral IEN and oral SCCs (4, 6), this location was selected as the site for gel application by the normal participants. These patients followed the same 10% FBR gel application course regimen (i.e., 0.5 g applied four times daily for

6 wk). All participants were monitored during the 6-wk treatment course to observe for any adverse side effects and, in the persons with premalignant lesions, any clinical progression in lesional tissue. All patients returned their used gel tubes at each weekly follow-up visit. Toxicity was assessed using the National Cancer Institute Common Toxicity Criteria version 2.0. Any toxicity grade  $\geq 2$  was considered dose limiting.

Following the 6-wk gel application period, clinical photographs were taken and biopsies were obtained from the treated ventrolateral tongue of the normal participants. In the persons with premalignant lesions, excisional biopsies, which included the residual treated lesional tissue and initial biopsy site, were conducted. Tissue samples were handled as previously described.

Light microscopic diagnoses of all tissues were based on a seven-grade scale (normal, hyperkeratosis, atypia, mild dysplasia, moderate dysplasia, severe dysplasia, carcinoma *in situ*, and invasive SCC). In this study, the diagnosis "hyperkeratosis" alone conveyed a benign, reactive change without evidence of premalignant potential. In contrast, "atypia" signified architectural and cytologic alterations that in the clinical setting of an adherent well-delineated white plaque represent early premalignant change. Given that histopathologic evaluation of oral dysplasia, particularly that of early lesions (atypia versus mild dysplasia), often confers a degree of subjectivity (34), two board-certified oral and maxillofacial pathologists reached agreement before a final diagnosis was rendered.

**Tissue microdissection and DNA isolation.** Premalignant oral epithelium and the corresponding histologically normal connective tissue were independently captured from 8- $\mu$ m tissue sections using the Arcturus AutoPix Automated Laser Capture Microdissection instrument (Molecular Devices). Approximately 2,700 laser hits for epithelium and 5,000 hits for the less cellular underlying connective tissue, with a variable spot size of 14 to 30  $\mu$ m, were used to acquire an adequate sample. Two laser capture microdissection samples, composed of lesional epithelium and underlying connective tissue, were collected from the pretreatment, baseline specimens per patient. After treatment, two laser capture microdissection samples (epithelium and connective tissue) were collected from each marked location



(initial biopsy site and residual lesion site) for a total of four posttreatment laser capture microdissection tissues. DNA extraction was done using the PicoPure DNA Extraction kit (Arcturus Bioscience, Inc.) per the manufacturer's instructions. Connective tissue and epithelial DNA were also captured and isolated from the normal participants' tissues.

**PCR amplification and analysis.** Genomic DNA was amplified using primer sequence information from Invitrogen to create custom primers (Applied Biosystems, Inc.) containing a 5' fluorescent label on the forward amplification primer. LOH markers were selected to target known and presumed tumor suppressor gene loci, which have previously been reported as exhibiting LOH in oral IEN lesions. Selected markers and their corresponding loci were as follows: 3p14.2-3p21.1 (D3S1234 and D3S1300), 9p21 (D9S171, D9S1751, and D9S1748), 9p22 (IFN $\alpha$ ), and 17p13 (D17S786 and TP53). A 20  $\mu$ L PCR mixture of 1 $\times$  PCR buffer, 0.5 mmol/L deoxynucleotide triphosphate, 1.5 to 5.5 mmol/L MgCl<sub>2</sub>, 0.5  $\mu$ mol/L of each primer, 2.5 units of Platinum Taq DNA polymerase, and 3  $\mu$ L of genomic DNA was amplified using a Bio-Rad iCycler thermal cycler. PCR conditions entailed 95°C for 2 min followed by 40 cycles of 95°C for 50 s, 55°C or 59°C for 50 s, 72°C for 50 s, and a final elongation step of 72°C for 7 min.

**Allelic imbalance.** Fragment analysis was done at the Plant Microbe Genomics Facility at The Ohio State University using the Applied Biosystems 3730 sequence analyzer. In brief, 1  $\mu$ L of PCR product DNA was added to 9  $\mu$ L HiDi (formamide; Applied Biosystems) and 0.2 or 0.4  $\mu$ L GeneScan 500 LIZ Size Standard (Applied Biosystems) for analysis. Multiplex analysis paired compatible dyes with amplified fragments of differing length, facilitating peak identification and separation. Multiplex combinations were as follows: D3S1234 and D3S1300, D9S171 and D17S786, D9S1751 and D9S1748, and IFN $\alpha$  and TP53. Electropherogram data were analyzed using GeneMapper software v4.0 (Applied Biosystems) using both automatic settings and manual editing for allele identification. Peak intensities  $\leq$ 50 relative fluorescent units were excluded for being within background. Normal

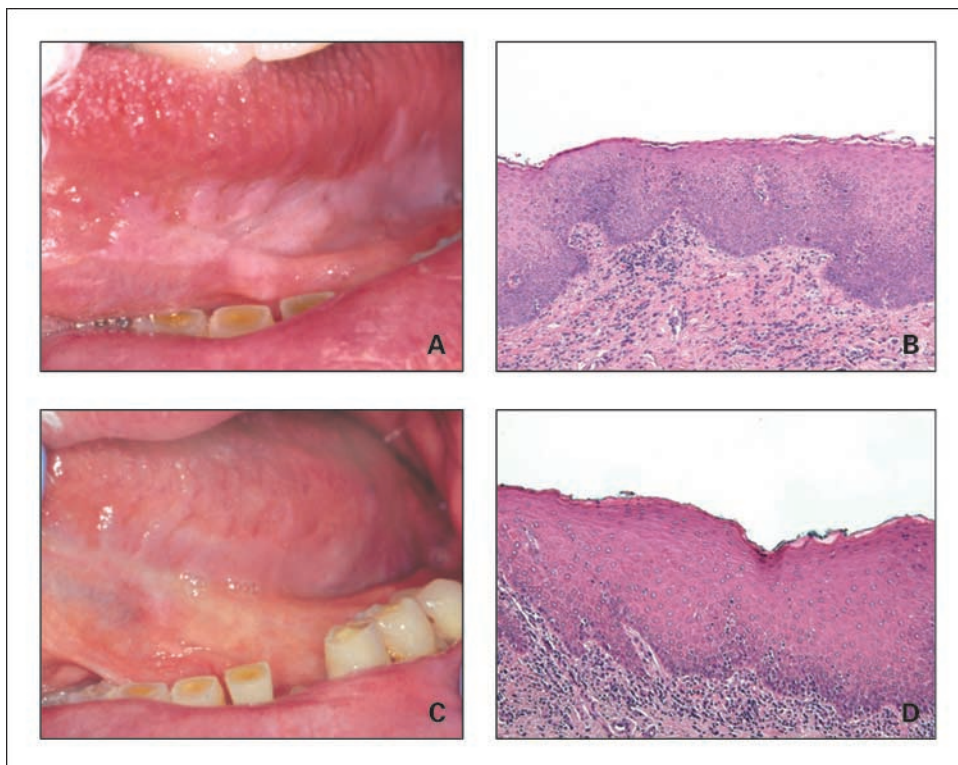
participant samples were used to establish microsatellite marker peak patterns and allele sizes. Inpatient comparisons of all six available samples (epithelial and connective tissues) in the IEN participants' tissues (two pretreatment and four posttreatment) facilitated allele identification. Patient-matched normal connective tissue samples with only one allele were deemed "not interpretable." In several instances, the PCR amplification products in the patient-matched normal connective tissue for a particular patient/marker combination were inadequate to allow LOH determination and were designated as "not available." LOH determinations were made using a modification of the protocol established by Canzian et al. (35), using an increased level of stringency (>50% reduction in peak intensity) to accept the presence of LOH (36). Three biopsy specimens (pretreatment, posttreatment biopsy site, and posttreatment residual lesion site) from the 17 oral IEN patients were examined with eight markers for a total of 408 potential events of LOH in the premalignant lesional tissues.

**Statistical analyses.** Due to the small sample size, all analyses were conducted using nonparametric exact tests. The exact McNemar test was used to evaluate all pretreatment to posttreatment changes in LOH. Associations between patient demographics and changes in LOH and histologic grade were analyzed using Fisher's exact test. A categorical score for LOH and histologic grade changes (increased, decreased, or stable disease) was assigned for each patient and comparison was made using the Spearman's rank correlation coefficient. Findings with a *P* value of <5% were considered to be significant (*P* < 0.05).

## Results

**Berry gel application does not elicit any toxic effects and does not perturb clinically normal oral mucosa.** None of the 27 trial participants developed any adverse effects, such as mucositis or xerostomia, during the 6-week treatment. In addition, the tissues at the treated site retained a normal clinical appearance in the normal tissue participants. Finally, the microscopic

**Fig. 2.** A subset of oral IEN participants showed marked clinical and histologic improvements following a 6-wk application of the 10% berry gel. The pretreatment clinical appearance of the left ventral tongue lesion depicted in *A* (patient #10) shows a lesion showing marked hyperkeratosis with crisp demarcation of lesional tissue. The corresponding pretreatment biopsy (*B*, 100 $\times$  image scale, diagnosed as mild to moderate dysplasia) shows characteristic dysplastic features, including basilar hyperplasia, increased nuclear to cytoplasmic ratios, and bulbous epithelial rete ridges. *C*, clinical regression, as evidenced by overall loss in lesional tissue delineation and reduction in hyperkeratosis, is evident in the posttreatment photograph. The corresponding posttreatment histopathology (*D*, 100 $\times$  image scale, diagnosed as hyperkeratosis and atypia) reveals a more appropriate maturational pattern characterized by a reduction in basilar hyperplasia and a reduction in the nuclear to cytoplasmic ratios.



**Table 2.** Oral IEN patient LOH prevalence pretreatment

Locus	Microsatellite markers	NA	NI	LOH	Interpretable samples	% LOH of interpretable samples	Patients with $\geq 1$ event of LOH
3p14	D3S1234; D3S1300	2	9	3	23	13.0	3
9p21-22	D9S171; D9S1751; D9S1748; IFN $\alpha$	5	19	20	44	45.5	10
17p13	D17S786; TP53	3	5	4	26	15.4	3
Combined	All markers	10	33	27	93	29.0	10*

Abbreviations: NA, data not available or not evaluable due to inadequate PCR amplification; NI, not interpretable, which indicates the presence of only one allele in the IEN participant-matched connective tissue.

\*Only patients with LOH at 9p21-22 exhibited additional imbalance at other loci.

appearances of all 10 normal patients' tissues showed healthy ventrolateral tongue tissues (data not shown). In addition, as determined by the minimal residual gel in the returned berry gel tubes, patient compliance was high (>95%).

**Premalignant oral lesion participant demographics and histopathologic diagnoses.** Table 1A depicts the demographics and pretreated and posttreated histopathologic diagnoses of the 17 participants with IEN lesions. Follow-up information on the disease status of a subset of this patient cohort (Table 1B) following the clinical trial is discussed later. The IEN participants were older than the normal patient cohort (mean, 59 years of age), with only one participant <43 years of age. Not surprisingly, the majority of participants had a previous history of smoking (70.5%) and also currently used alcohol (58.8%). Of those patients with a history of smoking, two (#9 and #17) quit 6 weeks before participation in the trial. Further, over three fourths (82%) of the participants had either multifocal lesions or a history of recurrent disease at the selected treatment site, factors associated with a higher-risk cohort. Histopathologic improvement, as determined by a decrease in lesional grade following treatment, was seen in seven participants' tissues (41%), disease progression (increase) in grade in 4 (23%), and six participants' tissues (35%) exhibited no change (stable disease) in microscopic appearance. Further, decrease in lesional grade was not restricted to lower-grade lesions, as some (24%) of the pretreatment diagnoses of the responsive lesions were severe or moderate dysplasia (Table 1A). The youngest participant (#9), who had three previous diagnoses of epithelial dysplasia at the treatment site, had complete clinical and microscopic lesional regression following treatment. Participants #4 (no histopathologic evidence of premalignant changes) and #16 (biopsy confirmed invasive oral SCC) did not meet the study criteria and were therefore excluded from participation. The posttreatment biopsy of patient #8 showed an increase of three grades, from mild dysplasia (pretreatment) to focal carcinoma *in situ* (posttreatment). The clinical protocol entailed hemisectioning lesional tissue, leaving half in place for the 6-week treatment. Participant #8's lesional tissue was remarkable for its extremely subtle clinical appearance, which introduced the prospect of sampling error at the pretreatment biopsy.

The effects of berry gel application on oral IEN clinical appearance were varied. Although complete clinical lesional regression was only observed in one participant (#9), varying degrees of clinical regression, including reduction in residual lesional size, extent of hyperkeratosis, and surface change

(Fig. 2), were noted in many IEN participants. Pretreatment lesional size had no readily discernible effect on posttreatment lesional appearance. Although one small pretreatment lesion (IEN #9) showed complete clinical and histologic regression, a comparably sized gingival lesion (IEN #6) showed return of similarly appearing lesional tissue following treatment. One of the most notable clinical regressions was observed in a large pretreatment lesion located on the lateral tongue (IEN #10).

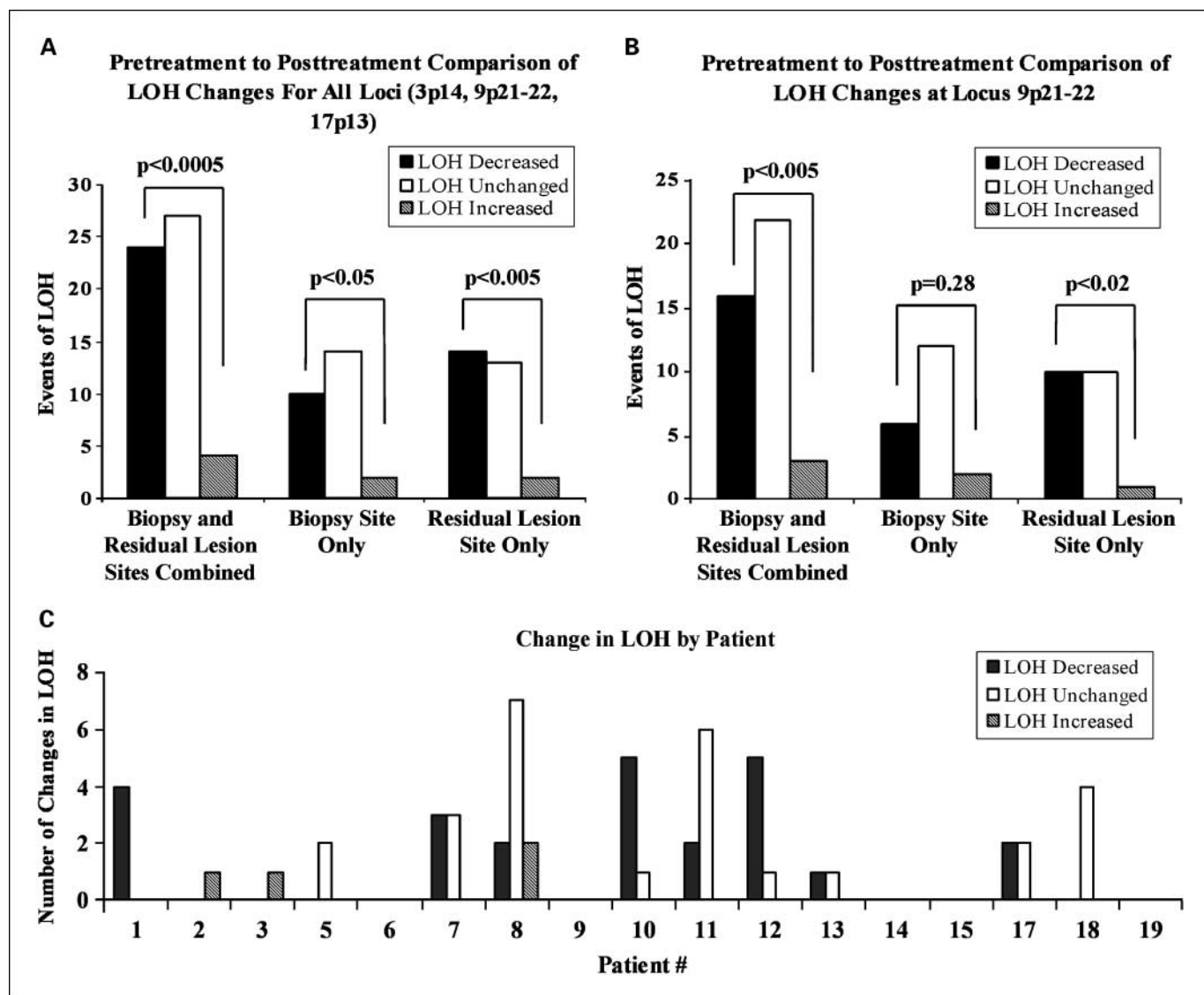
**Prevalence of LOH in pretreatment samples.** For the study population of 17 participants with oral IEN, there were 136 potential occurrences or events of LOH when comparing pretreatment lesional epithelium with patient-matched normal connective tissue (Table 2). Noninterpretable data, samples with a single allele in patient-matched normal connective tissue, and data that were not available due to inadequate PCR amplification with select patient/microsatellite marker combinations accounted for 43 (31.6%) of the potential LOH measurements. Notably, repeated PCR amplification and LOH analyses yielded an intraclass correlation coefficient of 0.914 with a 95% confidence interval of 0.828 to 0.961. Of the remaining 93 pretreatment interpretable measurements, 27 (29.0%) exhibited LOH. Combination of the four markers specific for 9p21-22 revealed a LOH prevalence of 45.5% in the pretreatment tissues. In addition, one or more of the eight markers exhibited LOH in 10 (58.8%) of the 17 participants' tissues (Table 2). At locus 9p21-22, 10 participants had LOH for at least one of the four markers examined such that when LOH was identified for markers specific for 3p14 or 17p13, LOH was always concurrently present at 9p21-22.

**Berry gel application significantly reduces LOH prevalence.** These analyses reflect any modifications in LOH events, which could be present either before, after, or both, for an individual marker in a particular patient. Each participant had two comparisons that were made pretreatment to posttreatment. One comparison was the tissue from the initial biopsy site relative to the posttreatment residual lesion and the other evaluation entailed comparison of the tissue from the initial biopsy site to tissue removed from the same location at the end of treatment (Fig. 1). Each patient, therefore, had two posttreatment areas, which could contribute to the overall potential events of LOH. Determination of LOH indices for all markers in each patient is depicted in Supplementary Table S1.

Changes in LOH status for all loci from pretreatment samples compared with both posttreatment samples combined (biopsy site + residual lesion site) showed a decrease in LOH

( $P < 0.0005$ ) in 24 events (Figs. 1 and 3A). An increase in LOH was noted in 4 instances, and 27 comparisons exhibited LOH at the beginning and end of the trial (no change). Site-specific examination (Fig. 3A) revealed a significant posttreatment decrease in LOH at the initial biopsy site (10 events,  $P < 0.05$ ) and the residual lesion site (14 events,  $P < 0.005$ ). No significant difference in the number of events of LOH decrease was observed between these two sites. Collective evaluation of a marker specific for 9p21-22 (D9S171, D9S1751, D9S1748, and IFN $\alpha$ ; Fig. 3B) showed a significant decrease in LOH (16 events,  $P < 0.005$ ). When examined individually, a significant decrease was also observed for the posttreatment residual lesion site (10 events,  $P < 0.02$ ) but not for the initial biopsy site (Fig. 3B).

**Effects of berry gel application on individual participants' LOH status.** Comparisons of the LOH alterations in the individual participants' tissues showed that five patients exhibited no LOH for any of the markers either before or after treatment (Fig. 3C; Table 3). Whereas three of these five patients had very early histologic alterations (hyperkeratosis and atypia), the other two individuals had more significant disease (one mild to moderate dysplasia and one moderate to severe dysplasia, former oral SCC resection site). Of the 12 remaining patients that exhibited LOH for any marker, 7 showed only a reduction in LOH events (range, 18.2-100%), with 6 of the 7 displaying a  $\geq 50\%$  reduction (Fig. 3C; Table 3). Of the other 5 of 12 patients with LOH, 2 showed an increase (1 event each), 2 yielded no change in LOH status, and 1 (#8) displayed a mixed



**Fig. 3.** Pretreatment to posttreatment comparisons of changes in LOH prevalence. *A*, changes in all events of LOH combined for the eight markers examined at three loci (3p14, 9p21-22, and 17p13). The initial biopsy site and residual lesion site are depicted together and separately. *B*, a subset of data from *A*, restricted to the changes in LOH observed for the four markers targeting locus 9p21-22. Small sample size precluded evaluation of the other two loci in this manner. *C*, individual patient changes in LOH prevalence. Each patient has three potential outcomes (decrease, no change, and increase) for each measurement of LOH. There are 16 total (8 from the biopsy site and 8 from the residual lesion site) measurements for each patient. Participants with no data entry did not exhibit LOH for any of the evaluated markers either before or after berry gel application.

**Table 3.** Comparison of changes in LOH and histopathologic grade

Locus	Events of LOH ↓ (improvement)			Events of LOH ↑ (progression)			Events of LOH unchanged (no effect)			Histopathologic Δ*
	3p14	9p21-22	17p13	3p14	9p21-22	17p13	3p14	9p21-22	17p13	
Patient no.										
1		4 (100)								-1
2				1 (100)						-1
3					1 (100)					-1
5								2 (100)		-1
6										0
7	1 (16.7)	2 (33.3)					1 (16.7)	2 (33.3)		0
8	2 (18.2)				2 (18.2)			4 (36.3)	3 (27.3)	3
9										-1
10		5 (83.3)						1 (16.7)		-2
11			2 (25)					6 (75)		1
12	1 (16.7)	2 (33.3)	2 (33.3)				1 (16.7)			0
13		1 (50)						1 (50)		0
14										-1
15										0
17		2 (50)						2 (50)		1
18								4 (100)		0
19										1

NOTE: For each column, the number of changes in LOH at a particular locus is given for each patient followed by the percentage, in parenthesis, of the total number of LOH events identified in that patient. LOH events listed include alterations at both the biopsy site and the residual lesion site. Blank spaces indicate that no LOH was identified.

\*A negative value indicates a decrease (improvement) in grade, whereas a positive value indicates an increase (progression) in grade. The values also reflect the magnitude of grade alteration. A zero value signifies that no change in grade was observed.

result (two events increased and two events decreased; Fig. 3C; Table 3).

**Correlation of LOH status change, histopathologic change, and demographic variables.** Comparison of individual patient alterations in LOH and histopathology yielded mixed results (see Tables 1 and 3). Whereas some of the seven patients who showed a decrease in histologic grade also exhibited a striking decrease in LOH (#1, four events; #10, five events), others showed an increase in LOH (#2 and #3, one event each) or no change (#5). Interestingly, within the four patients who exhibited histopathologic progression, LOH decrease (#11, #17, and #19, two events each) and a mixed result (#8, two events increased and two events decreased) were identified. Of the six patients with no change in histopathology, half showed LOH decrease (#7, #12, and #13) and half exhibited no change. Despite this marked interpatient heterogeneity, statistical comparison of these two outcome variables yielded a Spearman's rank correlation coefficient of 0.3504 ( $P < 0.05$ ), suggesting a modest positive association between a decrease in LOH events and improvement in histopathologic grade. There was no overall correlation between LOH status change or histopathologic change with regard to gender, smoking status, alcohol consumption, traditional high-risk sites (carcinogen pooling areas), and multifocal or recurrent disease. IEN participant age was not evaluated due to the fact that IEN participants' ages were tightly clustered.

**Follow-up information on clinical trial participants.** Follow-up information about study participants (Table 1B) is limited by the complexion of the patient pool in this regional referral center. Ten study participants remained as patients of record at Ohio State. Follow-up ranged from 3 to 20 months (mean, 11). In summary, three participants (#5, #9, and #15) had no

recurrence clinically at the treatment site with disease noted at other oral sites. Three patients (#3, #7, and #19) exhibited no change in disease at the treatment site, with two of these three (#3 and #19) showing progression at other locations. Four participants (#1, #2, #10, and #14) showed progression at the treatment site, one of which (#1) developed invasive disease. Two of these four patients (#2 and #14) had involvement of other sites. Notably, the private practice oral surgeons following the trial participants submit their tissue biopsies to The Ohio State University Oral Pathology Biopsy Service for microscopic diagnosis, and this service has not received any specimens from the other seven study participants since study completion.

## Discussion

Our results show that topical application of a bioadhesive 10% FBR gel positively affects oral IEN lesions in a subset of patients. Further, none of the 27 clinical trial participants developed any adverse effects. These encouraging toxicity data support previous studies conducted by our laboratories, which confirmed that large doses of FBR are well tolerated by humans (19–21), and further validate the established safety record for the two cross-linked polyacrylic acid-based polymers used as either the bioadhesive or the gel base (22).

Our histopathology data show appreciable interpatient variability in IEN responsiveness, with 41% of our participants showing a decrease in lesional grade, 23% of participants showing an increase in lesional grade, and 35% of the patients' lesions exhibiting stable disease. Although modest, these histologic response rates compare favorably with previous oral IEN chemoprevention trials (27). Indeed, it is possible that



optimized dose or dosing schedules may improve these outcomes. A former study, which evaluated the effects of 13-*cis*-retinoic acid,  $\alpha$ -tocopherol, and IFN $\alpha$  on oral and laryngeal IEN lesions, revealed that only 14% (1 of 7) of the oral dysplastic lesions showed partial histologic regression at the completion of the 12-month study, with 45% (5 of 11) showing either partial or complete regression at the intermediate 6-month assessment (27). Rates of histologic regression were higher in the laryngeal lesions, which led the authors to speculate that the more recalcitrant oral cavity lesions had sustained different, potentially greater molecular perturbations (27). At a mean follow-up of 11 months after treatment, 33% (3 of 10) showed no clinical evidence of disease at the treatment site and another 33% (3 of 10) had not progressed histologically. Interestingly, of the four patients who exhibited histologic progression after follow-up (#1, #2, #10, and #14), each had shown histologic improvement during the clinical trial. These data suggest that FBR may inhibit recurrence, slow disease progression, and be required as long-term therapy to maintain positive treatment effects.

Of note, it has been well described that accurate reproducibility in histopathologic distinction between adjacent (e.g., atypia and mild dysplasia) grades of oral epithelial dysplasia using strict criteria is difficult to achieve even among experienced oral and maxillofacial pathologists (34). This challenge is highlighted in this study as the majority of histopathologic changes noted were of a single-grade change. Thus, although agreement among two experienced examiners was used to optimize the accuracy of these results, these histopathology data should be interpreted in conjunction with the other outcomes measures studied and not as an isolated, rigorous criterion of therapeutic efficacy.

A range of responsiveness (from complete clinical regression to modest reduction) was noted in the clinical appearances of the treated lesions. Although assessment of lesional clinical size has been used as a therapeutic indicator (26, 27), we did not rely extensively on this variable for at least two reasons. First, as oral IEN lesions are dynamic, lesion appearance can vary from week to week regardless of therapeutic intervention (6). Second, previous studies have reported oropharyngeal IEN lesions that had undergone apparent clinical regression yet still retained dysplastic histology (27, 33). These data imply the potential for inflated rates of lesional regression if clinical measurements are used without histopathologic validation or consideration of the molecular profile (27, 33).

LOH is speculated to facilitate tumorigenesis by inactivation of one of the two alleles of tumor suppressor genes, with inactivation of the second allele occurring by other mechanisms, such as promoter methylation or point mutations. Furthermore, LOH at tumor suppressor gene-associated chromosomal loci has been linked with a higher risk for oral IEN progression to oral SCC (32). The pretreatment LOH indices determined in our study [i.e., 13% (3p14), 45% (9p21-22), and 15% (17p13)] are comparable with an initial study conducted by Mao et al. (which included nondysplastic lesions; ref. 32) but are lower than a second trial (restricted to moderate dysplasia or higher grade) by this same group (33). These interstudy LOH differences likely reflect baseline lesion histology, methods of LOH analysis, and molecular markers evaluated. Discordance between several of the study variables

(i.e., clinical and histologic response, and clinical response and LOH indices) was noted in the later study by Mao et al. (33). Although two of the treated oral IEN lesions showed apparent complete clinical regression, neither of these lesions possessed normal histology (33). Further, although five of nine oral and laryngeal lesions showed a clinical response, eight treatment sites retained LOH at 9p21 (33). In contrast, our posttreatment data show a positive association between reduction in histologic grade and decreases in LOH indices as well as significant LOH reduction. These different outcomes likely reflect interstudy differences that included chemopreventive compounds, treatment duration, method of delivery, and pretreatment protocol. Pretreatment biopsies, when conducted, were conservative in the former study (33). In contrast, our protocol introduced a wound from lesional hemisection. Epithelial wound repair is associated with activation of the transient amplifying and stem cell populations (37). Consequently, the normally quiescent stem cells, which are speculated to retain the acquired genetic perturbations in a cellular subpopulation, would enter a proliferative state (37). Previously, we have shown that a FBR extract activates apoptosis and terminal differentiation in human oral SCC cells (14). The clinical trial data suggest a similar mechanism as that observed *in vitro* (i.e., application of selective prodifferentiation and/or proapoptotic pressures on the LOH harboring epithelial cells by the FBR compounds), resulting in a reduction in LOH indices.

Our data reveal that a subset of oral IEN lesions responded favorably to topical berry gel application. Correlations among extent of disease, clinical location, social history, and positive treatment effects were not identified. The small sample size may have prevented an appreciation of relationships among these variables, if such associations exist. Another shortcoming of the current study was its short treatment duration. A larger-scale, longer-duration, placebo-controlled, multicentered clinical trial is planned to address these limitations. To augment gel formulation and potentially enhance oral IEN lesion responsiveness, studies are ongoing to delineate the contribution of potential confounding variables, such as sustainability of the agent at the treatment site, the ability of the gel to promote penetration of bioactive moieties, and the capacity for local tissue metabolism.

The method of agent delivery is one of the major factors that could have positively affected our trial. The coauthors of a recent fenretinide IEN chemoprevention trial speculated that their modest regression rate (34% by clinical measurement alone) and relatively high toxicity (43%) reflected an inability to obtain therapeutic levels at the lesional site from systemic administration (26). Further, although a mouthwash (ONXY-015) that used an adenovirus vector to target cells defective in p53 signaling showed promising clinical results, 14% (one of seven) of the participants evaluated developed circulating antiadenoviral antibody titers (29). Although FBR chemopreventive compounds such as the anthocyanins are generally not well absorbed from the gastrointestinal tract, our previous (22) and current data show that anthocyanins delivered via a bioadhesive gel were well absorbed at the human oral mucosal application site.

Due to many patients having a history of lesion recurrence and multifocal disease, the current study evaluated a high-risk patient cohort. Although limited, our follow-up data confirm

that longer-duration treatment will be necessary for many persons with oral IEN. Furthermore, provided the heterogeneous interpatient responses noted in our trial as well as others (26–29, 33), a single formulation is not likely to show chemopreventive efficacy in all oral IEN lesions. To help address these concerns, our laboratory is concurrently evaluating additional chemopreventive compounds and supplemental methods of local delivery, particularly for the management of higher-grade lesions or those shown to be recalcitrant to previous treatment(s) (38). The results from this initial pilot study, which show high tolerance and therapeutic efficacy in a subset of patients, imply that further evaluation of berry gel formulations for oral IEN chemoprevention is warranted.

## References

- Jemal A, Siegel R, Ward E, et al. Cancer statistics, 2007. *CA Cancer J Clin* 2007;57:43–66.
- Menzin J, Lines LM, Manning LN. The economics of squamous cell carcinoma of the head and neck. *Curr Opin Otolaryngol Head Neck Surg* 2007;15:68–73.
- Lang K, Menzin J, Earle CC, et al. The economic cost of squamous cell cancer of the head and neck: findings from linked SEER-Medicare data. *Arch Otolaryngol Head Neck Surg* 2004;130:1269–75.
- Neville BW, Day TA. Oral cancer and precancerous lesions. *CA Cancer J Clin* 2002;52:195–215.
- Silverman S, Jr., Gorsky M, Lozada F. Oral leukoplakia and malignant transformation. A follow-up study of 257 patients. *Cancer* 1984;53:563–8.
- Scuibba JJ. Oral leukoplakia. *Crit Rev Oral Biol Med* 1995;6:147–60.
- Lumerman H, Freedman P, Kerpel S. Oral epithelial dysplasia and the development of invasive squamous cell carcinoma. *Oral Surg Oral Med Oral Pathol Oral Radiol Endod* 1995;79:321–9.
- Silverman S, Jr., Gorsky M. Proliferative verrucous leukoplakia: a follow-up study of 54 cases. *Oral Surg Oral Med Oral Pathol Oral Radiol Endod* 1997;84:154–7.
- Lippman SM, Sudbo J, Hong WK. Oral cancer prevention and the evolution of molecular-targeted drug development. *J Clin Oncol* 2005;23:346–56.
- Sporn MB. Approaches to prevention of epithelial cancer during the preneoplastic period. *Cancer Res* 1976;36:2699–702.
- Huang C, Li J, Song L, et al. Black raspberry extracts inhibit benzo(a)pyrene diol-epoxide induced activator protein 1 activation and VEGF transcription by targeting the phosphatidylinositol 3-kinase/Akt pathway. *Cancer Res* 2006;66:581–7.
- Xue H, Aziz RM, Sun N, et al. Inhibition of cellular transformation by berry extracts. *Carcinogenesis* 2001;22:351–6. Erratum in: *Carcinogenesis* 2001;22:831–3.
- Huang C, Huang Y, Li J, et al. Inhibition of benzo(a)pyrene diol-epoxide-induced transactivation of activated protein 1 and nuclear factor  $\kappa$ B by black raspberry extracts. *Cancer Res* 2002;62:6857–63.
- Rodrigo KA, Rawal Y, Renner RJ, et al. Suppression of the tumorigenic phenotype in human oral squamous cell carcinoma cells by an ethanol extract derived from freeze-dried black raspberries. *Nutr Cancer* 2006;54:58–68.
- Casto BC, Kresty LA, Kraly CL, et al. Chemoprevention of oral cancer by black raspberries. *Anticancer Res* 2002;22:4005–15.
- Kresty LA, Morse MA, Morgan C, et al. Chemoprevention of esophageal tumorigenesis by dietary administration of lyophilized black raspberries. *Cancer Res* 2001;61:6112–9.
- Chen T, Rose ME, Hwang H, Nines RG, Stoner GD. Black raspberries inhibit *N*-nitrosomethylbenzylamine (NMBA)-induced angiogenesis in rat esophagus parallel to the suppression of COX-2 and iNOS. *Carcinogenesis* 2006;27:2301–7.
- Chen T, Hwang H, Rose ME, Nines RG, Stoner GD. Chemopreventive properties of black raspberries in *N*-nitrosomethylbenzylamine-induced rat esophageal tumorigenesis: down-regulation of cyclooxygenase-2, inducible nitric oxide synthase, and c-Jun. *Cancer Res* 2006;66:2853–9.
- Stoner GD, Sardo C, Apseloff G, et al. Pharmacokinetics of anthocyanins and ellagic acid in healthy volunteers fed freeze-dried black raspberries daily for 7 days. *J Clin Pharmacol* 2005;45:1153–64.
- Kresty LA, Frankel WL, Hammond CD, et al. Transitioning from preclinical to clinical chemopreventive assessments of lyophilized black raspberries: interim results show berries modulate markers of oxidative stress in Barrett's esophagus patients. *Nutr Cancer* 2006;54:148–56.
- Tian Q, Giusti MM, Stoner GD, et al. Urinary excretion of black raspberry (*Rubus occidentalis*) anthocyanins and their metabolites. *J Agric Food Chem* 2006;22:1467–72.
- Mallery SR, Stoner GD, Larsen PE, et al. Formulation and *in-vitro* and *in-vivo* evaluation of a mucoadhesive gel containing freeze dried black raspberries: implications for oral cancer chemoprevention. *Pharm Res* 2007;24:728–37.
- Smith W, Saba N. Retinoids as chemoprevention for head and neck cancer: where do we go from here? *Crit Rev Oncol Hematol* 2005;55:143–52.
- Toma S, Benso S, Albanese E, et al. Treatment of oral leukoplakia with  $\beta$ -carotene. *Oncology* 1992;49:77–81.
- Lippman SM, Batsakis JG, Toth BB, et al. Comparison of low-dose isotretinoin with  $\beta$  carotene to prevent oral carcinogenesis. *N Engl J Med* 1993;328:15–20.
- Lippman SM, Lee JJ, Martin JW, et al. Fenretinide activity in retinoid-resistant oral leukoplakia. *Clin Cancer Res* 2006;12:3109–14.
- Papadimitrakopoulou VA, Clayman GL, Shin DM, et al. Biochemoprevention for dysplastic lesions of the upper aerodigestive tract. *Arch Otolaryngol Head Neck Surg* 1999;125:1083–9.
- Shin DM, Mao L, Papadimitrakopoulou LM, et al. Biochemopreventive therapy for patients with premalignant lesions of the head and neck and p53 gene expression. *J Natl Cancer Inst* 2000;92:69–73.
- Rudin CM, Cohen EE, Papadimitrakopoulou VA, et al. An attenuated adenovirus, ONYX-015, as mouthwash therapy for premalignant oral dysplasia. *J Clin Oncol* 2003;21:4546–52.
- Kresty LA, Mallery SR, Knobloch TJ, et al. Alterations of p16 (INK4a) and p14 (ARF) in patients with severe oral epithelial dysplasia. *Cancer Res* 2002;62:5295–300.
- Pavelic K, Krizanac S, Cacev T, et al. Aberration of FHIT gene is associated with increased tumor proliferation and decreased apoptosis—clinical evidence in lung and head and neck carcinomas. *Mol Med* 2001;7:442–53.
- Mao L, Lee JS, Fan YH, et al. Frequent microsatellite alterations at chromosomes 9p21 and 3p14 in oral premalignant lesions and their value in cancer risk assessment. *Nat Med* 1996;2:682–5.
- Mao L, El-Naggar AK, Papadimitrakopoulou V, et al. Phenotype and genotype of advanced premalignant head and neck lesions after chemopreventive therapy. *J Natl Cancer Inst* 1998;90:1545–51.
- Abbey LM, Kaugars GE, Gunsolley JC, et al. Intra-examiner and interexaminer reliability in the diagnosis of oral epithelial dysplasia. *Oral Surg Oral Med Oral Pathol Oral Radiol Endod* 1995;80:188–91.
- Canzian F, Salvoara R, Hemminki A, et al. Semiautomated assessment of loss of heterozygosity and replication error in tumors. *Cancer Res* 1996;56:3331–7.
- van Houten VM, Tabor MP, van den Brekel MW, et al. Molecular assays for the diagnosis of minimal residual head-and-neck cancer: methods, reliability, pitfalls, and solutions. *Clin Cancer Res* 2000;6:3803–16.
- Mackenzie IC. Stem cell properties and epithelial malignancies. *Eur J Cancer* 2006;42:1204–12.
- Desai KGH, Mallery SR, Schwendeman SP. Formulation and characterization of injectable poly(DL-lactide-co-glycolide) implants loaded with N-acetylcysteine, a MMP inhibitor. *Pharm Res* [DOI:10.1007/s11095-007-9430-1]. 2007 Sept [cited 2008 Jan 12]. Available from: <http://www.springerlink.com/content/4n0128338228r000/>.

## Disclosure of Potential Conflicts of Interest

S.R. Mallery is a member of NanoMed's Pharmaceutical's Scientific Advisory Board and is the principal investigator on NanoMed's STTR grant on the topic of gel technology. R.J. Mumper is the founder of NanoMed Pharmaceuticals. All of the data and studies described in the current article were planned, conducted, and funded independently of NanoMed Pharmaceuticals.

## Acknowledgments

We thank Mike Zianni and staff at the Plant Microbe Genomics Facility (The Ohio State University) for their assistance with the LOH analyses; Eugene Leys, Ph.D. (Department of Oral Biology, The Ohio State University), who provided expert instruction in PCR methodology; Mary Lloyd, our histotechnologist, for laser capture microdissection specimen preparation; and Dr. Meng Tong for his assistance in image layout and construction.

# Clinical Cancer Research

## Effects of a Topically Applied Bioadhesive Berry Gel on Loss of Heterozygosity Indices in Premalignant Oral Lesions

Brian S. Shumway, Laura A. Kresty, Peter E. Larsen, et al.

*Clin Cancer Res* 2008;14:2421-2430.

**Updated version** Access the most recent version of this article at:  
<http://clincancerres.aacrjournals.org/content/14/8/2421>

**Supplementary Material** Access the most recent supplemental material at:  
<http://clincancerres.aacrjournals.org/content/suppl/2008/04/21/14.8.2421.DC1>

**Cited articles** This article cites 37 articles, 11 of which you can access for free at:  
<http://clincancerres.aacrjournals.org/content/14/8/2421.full#ref-list-1>

**Citing articles** This article has been cited by 9 HighWire-hosted articles. Access the articles at:  
<http://clincancerres.aacrjournals.org/content/14/8/2421.full#related-urls>

**E-mail alerts** [Sign up to receive free email-alerts](#) related to this article or journal.

**Reprints and Subscriptions** To order reprints of this article or to subscribe to the journal, contact the AACR Publications Department at [pubs@aacr.org](mailto:pubs@aacr.org).

**Permissions** To request permission to re-use all or part of this article, use this link  
<http://clincancerres.aacrjournals.org/content/14/8/2421>.  
Click on "Request Permissions" which will take you to the Copyright Clearance Center's (CCC) Rightslink site.