

Correlation of Osteopontin Protein Expression and Pathological Stage across a Wide Variety of Tumor Histologies

Domenico Coppola,^{1,2} Marianna Szabo,¹
David Boulware,² Patrick Muraca,³
Marwan Alsarraj,² Ann F. Chambers,⁴ and
Timothy J. Yeatman⁵

¹Department of Pathology, University of South Florida College of Medicine, Tampa, Florida; ²Department of Interdisciplinary Oncology, Moffitt Cancer Center and Research Institute, University of South Florida College of Medicine, Tampa, Florida; ³Clinomics BioSciences, Inc., Pittsfield, Massachusetts; ⁴London Regional Cancer Centre, London, Ontario, Ontario, Canada; and ⁵Department of Surgery, University of South Florida College of Medicine, Tampa, Florida

ABSTRACT

Purpose: Osteopontin (OPN) is an integrin-binding protein overexpressed in various experimental models of malignancy and appears to be involved in tumorigenesis and metastasis. Although various studies have assessed OPN protein levels in several tumor types, a broad survey of OPN expression in human neoplasia under the same experimental conditions has not been carried out.

Experimental Design: We used immunohistochemistry to detect OPN in a selection of 350 human tumors and 113 normal tissues, from a variety of body sites, using stage-oriented human cancer tissue arrays. Tumors included malignancies from breast (26), ovary (22), endometrium (14), esophagus (10), stomach (11), pancreas (16), bile duct (1), liver (9), colon (20), kidney (53), bladder (33), prostate (28), head and neck (60), salivary glands (14), lung (17), skin (6), and brain (10).

Results: High cytoplasmic OPN staining was observed in 100% of gastric carcinomas, 85% of colorectal carcinomas, 82% of transitional cell carcinomas of the renal pelvis, 81% of pancreatic carcinomas, 72% of renal cell carcinomas, 71% of lung and endometrial carcinomas, 70% of esophageal carcinomas, 58% of squamous cell carcinomas of the head and neck, and 59% of ovarian carcinomas. Although OPN expression was identified in a good number of

bladder, prostate, and brain tumors, the majority of 6 skin cancers, 11 of 14 salivary gland cancers, 2 thyroid carcinomas, and 23 of 26 breast cancers revealed low OPN positivity or were negative. When considering all sites, OPN expression significantly correlated with tumor stage (Spearman's correlation coefficient, $P = 0.0002$). OPN score and stage were also significantly correlated for specific cancer sites including bladder ($P = 0.01$), colon ($P = 0.004$), kidney ($P = 0.0001$), larynx ($P = 0.035$), mouth ($P = 0.046$), and salivary gland ($P = 0.011$).

Conclusions: This study reports the broad distribution of OPN in human tumors from different body sites, suggesting involvement of this protein in tumor formation. The strong correlation between pathological stage and OPN across multiple tumor types suggests a role for OPN in tumor progression.

INTRODUCTION

Osteopontin (OPN) is an integrin-binding protein, believed to be involved in a variety of physiological cellular functions (1). It has been shown to play an important role in tumorigenesis, tumor invasion, and metastasis in breast, lung, prostate, and colon cancers (2–8). The physiological functions of OPN are best documented in the bone where this secreted adhesive glycoprotein seems to be involved in osteoblast differentiation and bone formation, as well as in the anchorage of osteoclasts to bone and consequent bone resorption (9, 10). OPN gene transcription in bone tissue is regulated by the interaction between transactivating factors and vitamin D3 responsive elements (11).

OPN was first implicated in malignancy by *in vitro* studies detecting increased levels of OPN expression after cell transformation (12, 13) and from the observation that tumor cells with high metastatic potential had increased OPN expression (14–17). OPN protein also plays a role in immune functions (18) and in vascular remodeling (19). OPN is secreted into various body fluids including blood, urine, milk, and cochlear fluid (20, 21). The low baseline concentration of circulating OPN has been found to be elevated in patients with breast, prostate, and other cancers, and in some studies elevated plasma OPN has been shown to be associated with poor patient survival (22–25). OPN levels in tumor tissue have also been associated with tumor progression in breast, lung, prostate, and colon cancer (2–5, 26).

OPN has been shown to have the following cell adhesion properties: it can bind integrins, in particular $\alpha_v\beta_3$ (vitronectin receptor; 27) but also $\alpha_v\beta_1$, $\alpha_v\beta_5$ (28, 29) and the hyaluronic acid receptor CD44 (30) and/or its variants (31). It has been shown that the RGD (Arg-Gly-Asp) amino acid sequence of OPN is crucial for the ability of OPN to support cell adhesion and chemotaxis (32, 33). OPN thus may contribute to tumor invasion and metastasis via integrin-mediated signaling (1, 6, 7, 34).

Received 11/18/02; revised 5/23/03; accepted 9/18/03.

Grant support: USPHS Grant CA85052-01-A1 (to T. J. Y.), National Cancer Institute Grant CA85429-01 (to T. J. Y.), Canadian Breast Cancer Research Initiative Grant 12078 (to A. F. C.), and American Cancer Society Grant RPG0023401-CNE (to D. C.).

The costs of publication of this article were defrayed in part by the payment of page charges. This article must therefore be hereby marked *advertisement* in accordance with 18 U.S.C. Section 1734 solely to indicate this fact.

Requests for reprints: Timothy J. Yeatman, Department of Interdisciplinary Oncology/Pathology, Moffitt Cancer Center and Research Institute, University of South Florida, College of Medicine, 12902 Magnolia Drive, Tampa, Florida 33612-9497. Phone: (813) 972-8400, extension 7291; E-mail: yeatman@moffitt.usf.edu.

Tissue distribution of OPN has been examined previously in normal and tumor tissues, by both immunohistochemistry and *in situ* hybridization (26, 35, 36). However, a systematic assessment of OPN protein levels in a large series of human tumors and normal tissue has not been undertaken previously. Here, we define the distribution of OPN expression in a group of 350 human cancers from a large variety of anatomical sites and in 113 corresponding normal tissues from the same sites. The detection of OPN was performed under the same experimental conditions allowing the accurate comparison of the stain between tumors of different type and between tumors of the same histological type.

MATERIALS AND METHODS

Human Tissues. Using stage-oriented human cancer tissue arrays (catalogue no. CR250 and HDCS 010202; Clinomics Laboratory, Inc., Frederick, MD), 463 tissue samples (350 tumors and 113 normal tissues) were analyzed for OPN expression by immunohistochemistry. Each tissue sample evaluated was approximately 0.1 cm. Each type of tumor (approximately 50% of the total number) was represented in each of two different arrays (CR250 and HDCS 010202). The tumors included invasive ductal carcinomas from breast (26), papillary serous cystadenocarcinomas of the ovary (22), endometrial adenocarcinomas (14), esophageal squamous cell carcinomas (10), gastric adenocarcinomas (11), pancreatic duct adenocarcinomas (16), liver (9 total, 8 metastatic adenocarcinomas and 1 hepatocellular carcinoma), bile duct carcinoma (1), colonic adenocarcinomas (20), transitional cell carcinomas of renal pelvis (17), renal cell carcinomas (36), transitional cell carcinomas of the bladder (33), prostatic adenocarcinomas (28), head and neck squamous cell carcinomas [including cancers of lip (9), tongue (22), mouth (19), pharynx (5), larynx (3), and thyroid carcinomas (2)], salivary gland carcinomas (14 total; 3 acinic cell carcinomas, 4 mucoepidermoid carcinomas, and 7 pleomorphic adenomas), lung carcinomas (17 total; 7 adenocarcinomas, 8 squamous cell carcinomas, 2 adenosquamous carcinomas), skin tumors (6 total; 4 melanomas, 2 basal cell carcinomas), and brain tumors (10 total; 5 astrocytoma, 3 glioblastomas multiformes, 2 meningiomas). Normal tissues (113) from breast, stomach, colon, pancreas, liver, kidney, prostate, head and neck, salivary gland, thyroid, lung, brain, heart, skeletal muscle, adrenal, lymph nodes, spleen, and testicles were also included. The cancer patients had an average age of 63.2 years (ranging from 18 to 93 years). Two hundred and twenty were male, and 130 were female. The tumors ranged in size between 0.5 and 18 cm. The tumors were staged according to the Tumor-Node-Metastasis system, following the recommendations of the American Joint Committee on Cancer, 1988. The stage of the tumors was as follows: 128 patients had stage I, 81 stage II, 65 stage III, and 37 stage IV disease. In 39 patients, the stage was not known.

Immunohistochemistry. Anti-OPN murine monoclonal antibody (mAb53, prepared against recombinant glutathione *S*-transferase human OPN fusion protein, dilution at 1:1000; Refs. 26 and 33) was applied to 3 μ m sections from formalin-fixed, paraffin-embedded tissue specimens, using the avidin-biotin-peroxidase complex method (Vectastain Elite ABC kit; Vector, Burlingame, CA), following the manufacturer's instruc-

Table 1 Results of immunohistochemical analyses for both tumor and normal tissues

Tumor type	Number	OPN ^a Allred score			
		0	1 to 3	4 to 6	7 to 8
Bile duct	1	0	0	1	0
Bladder	33	9	6	11	7
Brain	10	2	2	6	0
Breast	26	15	8	3	0
Colon	20	1	2	9	8
Endometrium	14	2	2	4	6
Esophagus SCC	10	2	1	6	1
Kidney	36	8	2	19	7
Larynx SCC	3	1	1	1	0
Lip SCC	9	1	1	3	4
Liver	9	5	0	4	0
Lung	17	2	3	11	1
Mouth SCC	19	3	4	10	2
Ovarian	22	7	2	8	5
Pancreas	16	2	1	4	9
Pharynx SCC	5	2	1	2	0
Prostate	28	9	7	10	2
Renal pelvis	17	2	1	14	0
Salivary gland	14	10	1	3	0
Skin	6	4	0	1	1
Stomach	11	0	0	6	5
Thyroid	2	2	0	0	0
Tongue SCC	22	5	3	13	1
Total tumors	350	94	48	149	59
Normal tissues	113	51	27	28	7

^a OPN, osteopontin; SCC, squamous cell carcinoma.

tions. In brief, the immunostaining was performed manually at room temperature. Endogenous peroxidase and nonspecific background staining were blocked by incubating slides with 3% aqueous hydrogen peroxide for 10 min. After washing with PBS for 5 min, slides were blocked with normal serum for 20 min, followed by incubation with the anti-OPN primary antibody, at the dilution given, for 60 min. After rinsing with PBS for 5 min, sections were incubated with a biotinylated secondary antibody for 20 min. After washing with PBS for 5 min, slides were incubated with avidin-biotin complex for 30 min and washed again. Chromogen was developed with 10 mg of 3,3'-diaminobenzidine tetrahydrochloride (Sigma, St. Louis, MO) diluted in 12 ml of Tris buffer (pH 7.6) for 2 min. All samples were lightly counterstained with Mayer's hematoxylin for 30 s before dehydration and mounting. No antigen retrieval was performed. Positive controls and nonimmune protein-negative controls were used for each section. A section of colon cancer proven previously to be OPN positive by Western blot (5) was used as a positive control. Mouse IgG was used as the negative control serum.

Tumor staining was semiquantitatively examined by a pathologist (D. Coppola) using the Allred 8-unit system (37). For each tumor, represented by one slide, we determined the tumor epithelial cells proportion score and intensity score. Peritumoral inflammatory and stromal cells were not included in the evaluation. The proportion score included the fraction of positively stained tumor cells and was as follows: 0 = none, 1 = <1/100th; 2 = 1/100th to 1/10th; 3 = 1/10th to 1/3; 4 = 1/3 to 2/3; 5 = >2/3. The estimated average staining intensity of the

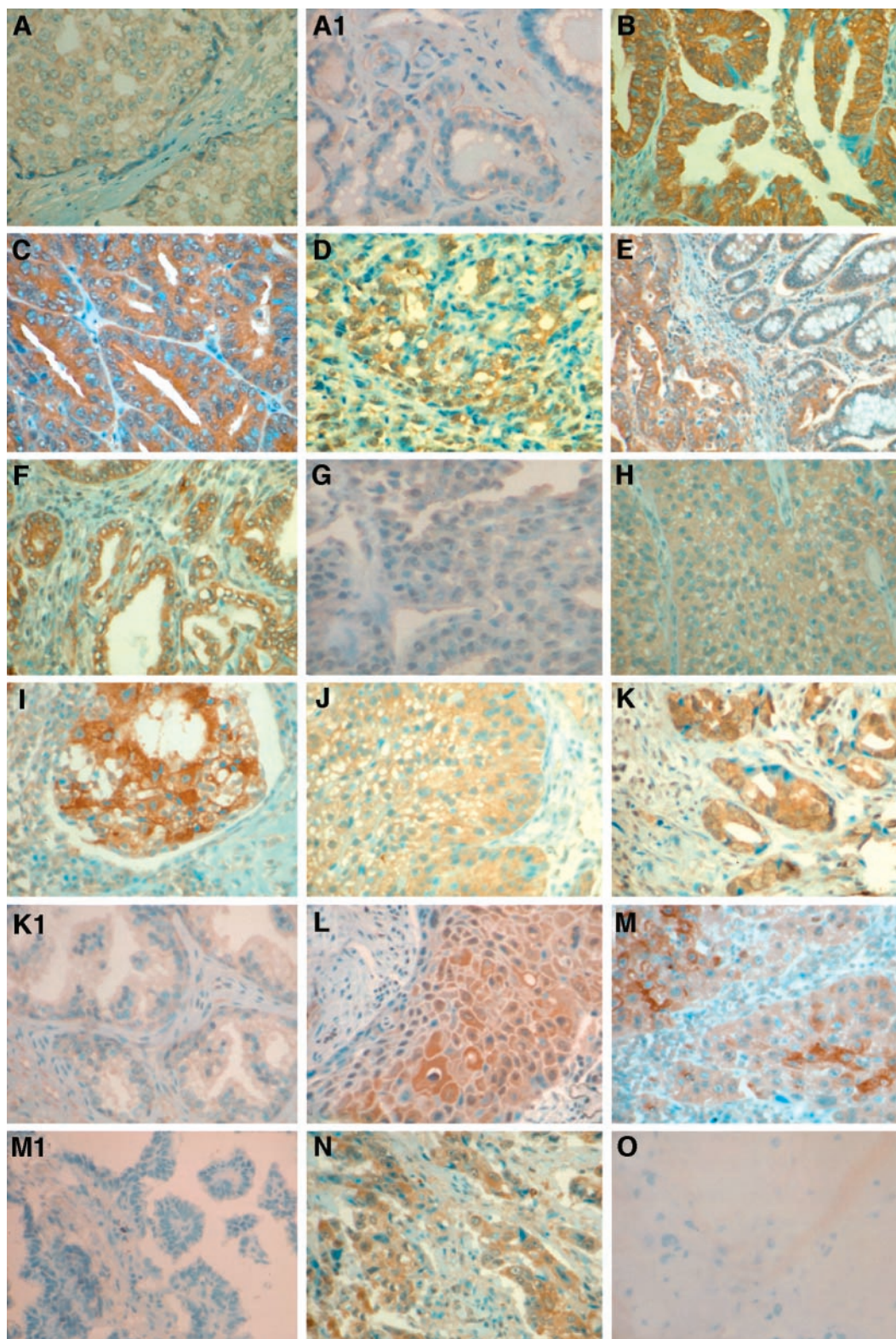


Fig. 1 Breast ductal carcinoma expressing low levels of OPN (A) is compared with normal breast tissue showing only faint and focal OPN stain (A1). High cytoplasmic OPN expression is shown in cases of ovarian papillary serous cystadenocarcinoma (B), endometrial adenocarcinoma (C), gastric adenocarcinoma (D), colon adenocarcinoma (E), pancreatic ductal carcinoma (F), renal cell carcinoma (I), transitional cell carcinoma of bladder (J), squamous cell carcinoma of the mouth (L), squamous cell carcinoma of the lung (M), and adenocarcinoma of the lung (N). OPN was not detected in hepatocellular carcinoma (G), bronchioloalveolar carcinoma of the lung (M1), or in normal prostatic tissue (K1). In H is a renal pelvis transitional cell carcinoma showing low OPN stain ($\times 400$).

positive tumor cells was expressed as follows: 0 = none; 1 = weak; 2 = intermediate; 3 = strong (37). For the statistical analysis an OPN score of 1–3 was considered low, an OPN score of 4–6 was considered intermediate, and an OPN score of 7–8 was considered high.

Statistical Analysis. The immunohistochemical results were analyzed by using the nonparametric Spearman's correlation coefficient method. A test was run for all sites combined and one for each of the site groupings.

RESULTS

Significant cytoplasmic OPN staining (score of 4 to 8) was observed in 11 of 11 (100%) gastric carcinomas; 17 of 20 (85%) colon carcinomas, 14 of 17 (82%) transitional cell carcinomas of the renal pelvis, 13 of 16 (81%) pancreatic carcinomas, 26 of 36 (72%) of renal cell carcinomas; 12 of 17 (71%) lung carcinomas, and 10 of 14 (71%) endometrial adenocarcinomas. One bile duct carcinoma also showed marked OPN protein expression (Allred score 6). Of the ovarian carcinomas 13 of 22 (59%) revealed significant OPN expression (Allred score between 4 and 8); however, 7 tumors were negative. Seven of ten (70%) esophageal squamous cell carcinomas also had high levels of OPN expression (Allred score 4–8). We found OPN expression at high levels (Allred score 4–8) also in 12 of 28 (43%) prostatic carcinomas, 35 of 60 (58%) head and neck squamous cell carcinomas; 4 of 9 (44%) liver tumors (the one hepatocellular carcinoma showed no expression of OPN), 18 of 33 (54%) bladder transitional cell carcinomas, and 6 of 10 brain tumors. Of the 17 lung tumors, 2 lung adenocarcinomas demonstrated no OPN expression; 3 primary squamous cell carcinomas revealed minimal OPN stain (Allred score 1–3). Interestingly, 15 of 26 (58%) breast carcinomas were negative, and 8 of them had low Allred score (1–3). Only 3 of 26 breast cancers expressed a significant level of OPN (Allred score 4–6). Another tumor exhibiting minimal expression of OPN was the salivary gland carcinoma; 10 of 14 cases were negative, 1 revealed OPN score of 1–3, and only 3 had intermediate OPN expression (score 4–6). In the skin, 4 melanomas were OPN negative, and 2 basal cell carcinomas had significant OPN expression (OPN score 6 and 8, respectively). In all tumor types, the stain was preferentially cytoplasmic. Occasional peritumoral inflammatory cells (macrophages) exhibited positive OPN stain. Of the normal tissues 69% showed negative or minimal OPN stain (Allred score 1–3), and only 7 of 113 (6%) samples had an OPN Allred score of 7–8 (high). Among the normal tissues expressing high OPN are liver (2), lymph nodes (2), testis (1), and spleen (2). When present, OPN positivity in the normal tissues was localized to the epithelia, without preferential luminal localization. The stroma surrounding the epithelia was OPN negative, but OPN positivity was identified within the surrounding inflammatory cells (macrophages) when present (Fig. A1, E, and K1). The results of the immunohistochemical analyses for both tumor and normal tissues are reported in Table 1 and Fig. 1.

To study the possible correlation of OPN expression and tumor progression, the OPN score was compared with tumor stage. OPN expression was found to be positively correlated with tumor stage using a Spearman's correlation coefficient. This correlation was still significant when male ($r_s = 0.218$,

$P = 0.0021$) and female ($r_s = 0.214$, $P = 0.0224$) were considered independently, and when individuals ≤ 65 years of age ($r_s = 0.218$, $P = 0.039$) and >65 years of age ($r_s = 0.214$, $P = 0.001$) were considered independently. When considering all sites, this correlation was highly significant ($r_s = 0.213$, $P = 0.0002$). Moreover, significant statistical correlation between OPN score and stage was also observed for specific site cancer groupings including bladder ($r_s = 0.432$, $P = 0.01$), colon ($r_s = 0.619$, $P = 0.004$), kidney ($r_s = 0.641$, $P = 0.0001$), larynx ($r_s = 0.586$, $P = 0.035$), mouth ($r_s = -0.462$, $P = 0.046$), and salivary gland ($r_s = 0.654$, $P = 0.011$). For ovarian cancers, the correlation approached significance ($r_s = 0.412$, $P = 0.057$). A valid test could not be applied to some of the site groupings (tumors of the bile duct, brain, esophagus, lip, liver, prostate, skin, and thyroid), either because of the few cases per group or because all of the tumors had the same stage value (Tables 1 and 2). No correlation was found between OPN expression and tumor grade.

DISCUSSION

In the last decade, several studies have defined an important role of OPN in carcinogenesis and metastasis. OPN is a calcium-binding phosphoprotein with multiple functions. Under physiological conditions, OPN is produced by osteoblasts, when stimulated by calcitriol, and it functions by binding to hydroxyapatite to provide the anchoring of osteoclast to the mineral of bone matrix (9–11). OPN binds to cells via the vitronectin receptor ($\alpha_v\beta_3$ integrin; Ref. 27) but also via other integrins and

Table 2 Correlation of OPN protein expression and tumor stage

Site	Spearman correlation (r_s)	N	P value
All sites	0.213	311	0.0002
Male	0.218	197	0.0021
Female	0.214	114	0.0224
65 and under	0.16	166	0.039
Over 65	0.27	145	0.001
Bile duct		1	
Bladder	0.432	33	0.012
Brain		10	
Breast	0.090	21	0.699
Colon	0.619	20	0.004
Endometrium	0.318	14	0.268
Esophagus		3	
Kidney	0.641	31	0.0001
Larynx	0.586	13	0.0352
Lip ^a		9	
Liver		9	
Lung	0.025	17	0.923
Mouth	-0.462	19	0.046
Ovary	0.412	22	0.057
Pancreas	0.281	11	0.403
Pharynx	0.236	4	0.764
Prostate ^a		28	
Renal pelvis	.084	16	0.76
Salivary	0.654	14	0.011
Skin		1	
Stomach	-0.058	11	0.865
Thyroid		2	
Tongue	0.305	22	0.167

^a All of the observations in this site had the same stage value, making a valid correlation impossible.

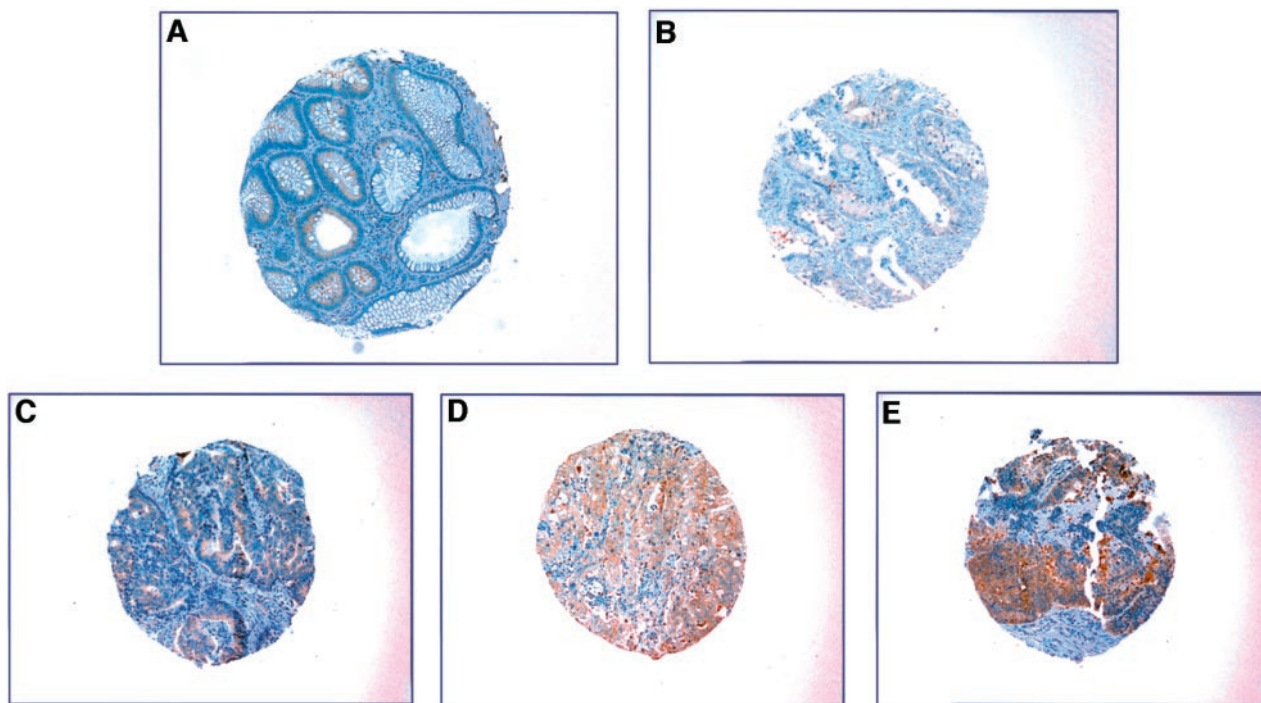


Fig. 2 Progressive increase in OPN expression in different stages of colon adenocarcinoma. Low expression of OPN is noted in adenoma (A) and in stage I ($T_1N_0M_0$) cancer (B). In A, the normal colonic mucosa adjacent to the adenoma is OPN negative. The increasing degree of staining intensity is noted from stage IIA ($T_3N_0M_0$) to stage IIIB ($T_4N_1M_0$) to stage IV ($T_3N_1M_1$) adenocarcinoma. Tumors were staged according to the Tumor-Node-Metastasis system, following the recommendations of the American Joint Committee on Cancer, 1992.

the hyaluronic acid receptor CD44 (27–31). OPN is also up-regulated in several pathological contexts, including immune reactivity, vascular remodeling, and cancer (1, 6–8, 10, 19).

In this study, we assessed the distribution of OPN protein by immunohistochemistry in a large variety of human tumor types from different anatomical sites. We used tissue array technology, which allows studies of this magnitude to be performed at a reasonable cost and has the advantage of minimizing experimental variations. For these reasons, we were able to compare OPN expression among many tumors of different type or derivation.

Our findings demonstrate that OPN is expressed in a large percentage of the tumor types studied. Significant cytoplasmic OPN staining was observed in all of the gastric tumors but also in a large percentage of colon, pancreatic, renal, lung, endometrial, esophageal, and head and neck carcinomas. Conversely, high OPN staining was identified in only a few cases of the corresponding normal tissues (7 of 113). We also found OPN expression to be low or negative in the majority of breast, skin, and salivary gland tumors. This finding is consistent with previous studies that focused on OPN levels in breast tumor tissue (6, 26, 36), which found that OPN levels were low in breast tumors. Tuck *et al.* (26), using the same OPN antibody as used in the current study, reported that only 26% of 154 lymph node-negative breast tumors had any OPN staining in the tumor cells themselves, whereas the majority of tumors showed some staining in infiltrating macrophages and/or lymphocytes, and only 7% of the tumors showed OPN staining in the tumor cells

with an Allred score of >4 . Interestingly, however, in that study, using this as a cutoff score, elevated OPN was found to correlate with shorter disease-free and overall survival, suggesting that the presence of OPN even in a minority of tumor cells can be associated with poor patient survival. In agreement with previous reports and using a similar cutoff score (see Table 1), we also observed OPN staining in a minority of breast tumor cells as well as in the peritumoral chronic inflammatory infiltrate (26, 36), suggesting that both cell types may contribute to the OPN tissue production levels. Early reports have described positive OPN protein-staining cancer cells lacking OPN mRNA (38), suggesting that the OPN is produced by peritumoral inflammatory cells and is subsequently phagocytized by tumor cells. Others, however, have recently demonstrated the production of OPN mRNA in ovarian cancer cells and have proposed OPN as a diagnostic marker for ovarian cancer (25). Therefore, additional molecular studies are required to definitively demonstrate the cell/cells responsible for OPN protein synthesis. In this study, we show that whatever the origin of OPN synthesis (tumor cells, peritumoral inflammatory cells, or both), the increased OPN expression positively correlates with tumor stage when considering nearly all sites (bladder, colon, kidney, larynx, and salivary glands). We also confirm the previously reported significant correlation of OPN with colon cancer stage ($P = 0.004$; Ref. 5; Fig. 2). It was not possible to estimate the exact correlation between OPN score and the tumor stage of a subset of specific site groupings (bile duct, brain, esophagus, lip, liver, prostate, skin, and thyroid), because all samples from

these tumor types had identical stages. Interestingly, the mouth cancers demonstrated a significant negative correlation with OPN expression. This finding may indicate that the molecular pathways of progression associated with these cancers may be different from those associated with OPN overexpression.

This correlation between OPN and tumor stage most likely reflects the effect of OPN on cell migration. Previous studies have shown that OPN can support *in vitro* attachment for a variety of cell types (27–29, 31–33) and promote migration of inflammatory and tumor cells (6, 7, 34, 38, 39). The highly conserved amino acid motif (RGD) can contribute to the cell adhesive and chemotactic functions of OPN (6, 7, 32, 33). OPN may also bind CD44 and/or CD44 variants (30, 31). By binding to various cell surface receptors, OPN can induce changes in tumor cell gene expression, including induction of proteolytic enzymes and activation of growth factor kinases, which in turn may lead to increased cell motility and invasion (6, 7, 31, 32, 34). Furthermore, several lines of experiments have implicated OPN in angiogenesis, and vascular endothelial growth factor may induce expression of OPN as well as $\alpha_v\beta_3$ integrin in endothelial cells. The binding of OPN to $\alpha_v\beta_3$ integrin may also stimulate the migration of vascular smooth muscle cells (19, 27). The importance of OPN in tumorigenicity is supported by *in vitro* experiments showing that expression of antisense *OPN* RNA is able to reduce the tumorigenic capability of ras-transformed NIH 3T3 cells (25, 40). Furthermore, *in vivo* studies have demonstrated that OPN is preferentially expressed by tumor cells with invasive and metastatic properties, suggesting that it may be a marker of high-stage cancers (2–8, 25).

Recent reports have described estrogen- (41) and progesterone- (42) inhibitory regulation of OPN expression. In agreement with these reports, we found that male and female samples, when analyzed separately, still showed a significant correlation between OPN expression and stage, but the degree of significance was higher in males than females ($P = 0.00212$ versus $P = 0.0224$, respectively).

In conclusion, we detected OPN protein in a wide variety of common human tumors. OPN levels were maximal in tumors of gastrointestinal, genitourinary, and gynecological origin and minimal to negative in tumors of skin, brain, and salivary gland. The nearly ubiquitous expression of this protein may reflect its important role in physiological (*i.e.*, bone metabolism and angiogenesis) as well as pathological (*i.e.*, transformation, invasion, and metastasis) processes. Finally, we show, for the first time, a strong correlation between levels of OPN protein and tumor progression in multiple tumor types from different anatomical sites. This conclusion is consistent with our recent report of OPN as the lead candidate for a marker of colon cancer progression, using expression array profiling of multiple colon tumors of a range of stages (5). Together these findings support the idea that OPN may play a functional role in progression of colon and other tumors. Additional studies to test the validity of OPN as a marker of tumor stage for a variety of tumor types, as well as studies to further clarify the functional role of OPN in tumor cell behavior, are warranted.

ACKNOWLEDGMENTS

We thank Sandy Livingston (Tissue Pathology Core) at the H. Lee Moffitt Cancer Center, University of South Florida, for performing the immunohistochemistry.

REFERENCES

- Sodek, J., Ganss, B., and McKee, M. D. Osteopontin. *Crit. Rev. Oral Biol. Med.*, *11*: 279–303, 2000.
- Tuck, A. B., O'Malley, F. P., Singhal, H., Tonkin, K. S., Harris, J. F., Bautista, D., *et al.* Osteopontin and p53 expression are associated with tumor progression in a case of synchronous, bilateral, invasive mammary carcinomas. *Arch. Pathol. Lab. Med.*, *121*: 578–584, 1997.
- Chambers, A. F., Wilson, S. M., Kerkvliet, N., O'Malley, F. P., Harris, J. F., and Casson, A. G. Osteopontin expression in lung cancers. *Lung Cancer*, *15*: 311–323, 1996.
- Thalmann, G. N., Sikes, R. A., Devoll, R. E., Kiefer, J. A., Markwalder, R., Klima, I., *et al.* Osteopontin: possible role in prostate cancer progression. *Clin. Cancer Res.*, *5*: 2271–2277, 1999.
- Agrawal, D., Chen, T., Irby, R., Quackenbush, J., Chambers, A. F., Szabo, M., Coppola, D., and Yeatman, T. J. Osteopontin identified as lead marker of colon cancer progression, using pooled sample expression profiling. *J. Natl. Cancer Inst. (Bethesda)*, *94*: 513–521, 2002.
- Tuck, A. B., and Chambers, A. F. The role of osteopontin in breast cancer: clinical and experimental studies. *J. Mamm. Gland Biol. Neoplasia*, *6*: 419–429, 2001.
- Furger, K. A., Menon, R. K., Tuck, A. B., Bramwell, V. H., and Chambers, A. F. The functional and clinical roles of osteopontin in cancer and metastasis. *Curr. Mol. Med.*, *1*: 621–632, 2001.
- Oates, A. J., Barraclough, R., and Rudland, P. S. The role of osteopontin in tumorigenesis and metastasis. *Invasion Metastasis*, *17*: 1–15, 1997.
- Reinholt, F. P., Hultenby, K., Oldberg, A., and Heinegard, D. Osteopontin: a possible anchor of osteoclasts to bone. *Proc. Natl. Acad. Sci. USA*, *87*: 4473–4475, 1990.
- Giachelli, C. M., and Steitz, S. Osteopontin: a versatile regulator of inflammation and biomineralization. *Matrix Biol.*, *19*: 615–622, 2000.
- Staal, A., van Wijnen, A. J., Birkenhager, J. C., Pols, H. A. P., Prah, J., DeLuca, H., Gaub, M.-P., Lian, J. B., Stein, G. S., van Leeuwen, J. P. T. M., and Stein, J. L. Distinct conformations of vitamin D receptor/retinoid X receptor- α heterodimers are specified by dinucleotide differences in the vitamin D-responsive elements of the osteocalcin and osteopontin genes. *Mol. Endocrinol.*, *10*: 1444–1456, 1996.
- Senger, D. R., Asch, B. B., Smith, B. D., Perruzzi, C. A., and Dvorak, H. F. A secreted phosphoprotein marker for neoplastic transformation of both epithelial and fibroblastic cells. *Nature (Lond.)*, *302*: 714–715, 1983.
- Senger, D. R., Perruzzi, C. A., and Papadopoulos, A. Elevated expression of secreted phosphoprotein I (osteopontin 2ar) as a consequence of neoplastic transformation. *Anticancer Res.*, *9*: 1291–1300, 1989.
- Craig, A. M., Nemir, M., Mukherjee, B. B., Chambers, A. F., and Denhardt, D. T. Identification of the major phosphoprotein secreted by many rodent cell lines as 2ar/osteopontin: enhanced expression in H-ras-transformed 3T3 cells. *Biochem. Biophys. Res. Commun.*, *157*: 166–173, 1988.
- Craig, A. M., Bowden, G. T., Chambers, A. F., Spearman, M. A., Greenberg, A. H., Wright, J. A., McLeod, M., and Denhardt, D. T. Secreted phosphoprotein mRNA is induced during multi-stage carcinogenesis in mouse skin and correlates with the metastatic potential of murine fibroblasts. *Int. J. Cancer*, *46*: 133–137, 1990.
- Chambers, A. F., Behrend, E. I., Wilson, S. M., and Denhardt, D. T. Induction of expression of osteopontin (OPN; secreted phosphoprotein) in metastatic, ras-transformed NIH 3T3 cells. *Anticancer Res.*, *12*: 43–48, 1992.
- Oates, A. J., Barraclough, R., and Rudland, P. S. The identification of osteopontin as a metastasis-related gene product in a rodent mammary tumour model. *Oncogene*, *13*: 97–104, 1996.

18. Patarca, R., Saavedra, R. A., and Cantor, H. Molecular and cellular basis of genetic resistance to bacterial infection: the role of the early T-lymphocyte activation-1/osteopontin gene. *Crit. Rev. Immunol.*, *13*: 225–246, 1993.
19. Shijubo, N., Uede, T., Kon, S., Nagata, M., and Abe, S. Vascular endothelial growth factor and osteopontin in tumor biology. *Crit. Rev. Oncog.*, *11*: 135–146, 2000.
20. Senger, D. R., Peruzzi, C. A., Gracey, C. F., Papadopoulos, A., and Tenen, D. G. Secreted phosphoproteins associated with neoplastic transformation: close homology with plasma proteins cleaved during blood coagulation. *Cancer Res.*, *48*: 5770–5774, 1988.
21. Bautista, D. S., Saad, Z., Chambers, A. F., Tonkin, K. S., O'Malley, F. P., Singhal, H., Tokmakejian, S., Bramwell, V., and Harris, J. F. Quantification of osteopontin in human plasma with an ELISA: basal levels in pre- and postmenopausal women. *Clin. Biochem.*, *29*: 231–239, 1996.
22. Singhal, H., Bautista, D. S., Tonkin, K. S., O'Malley, F. P., Tuck, A. B., Chambers, A. F., and Harris, J. F. Elevated plasma osteopontin in metastatic breast cancer associated with increased tumor burden and decreased survival. *Clin. Cancer Res.*, *3*: 605–611, 1997.
23. Fedarko, N. S., Jain, A., Karadag, A., Van Eman, M. R., and Fisher, L. W. Elevated serum bone sialoprotein and osteopontin in colon, breast, prostate, and lung cancer. *Clin. Cancer Res.*, *7*: 4060–4066, 2001.
24. Hotte, S. J., Winquist, E. W., Stitt, L., Wilson, S. M., and Chambers, A. F. Plasma osteopontin: associations with survival and metastasis to bone in men with hormone-refractory prostate carcinoma. *Cancer (Phila.)*, *95*: 506–512, 2002.
25. Kim, J. H., Skates, S. J., Uede, T., Wong, K. K., Schorge, J. O., Feltmate, C. M., Berkowitz, R. S., Cramer, D. W., and Mok, S. C. Osteopontin as a potential diagnostic biomarker for ovarian cancer. *J. Am. Med. Assoc.*, *287*: 1671–1679, 2002.
26. Tuck, A. B., O'Malley, F. P., Singhal, H., Harris, J. F., Tonkin, K. S., Kerkvliet, N., Saad, Z., Doig, G. S., and Chambers, A. F. Osteopontin expression in a group of lymph node negative breast cancer patients. *Int. J. Cancer Predict. Oncol.*, *79*: 502–508, 1998.
27. Senger, D. R., Ledbetter, S. R., Claffey, K. P., Papadopoulos-Sergiou, A., Perruzzi, C. A., and Detmar, M. Stimulation of endothelial cell migration by vascular permeability factor/vascular endothelial growth factor through cooperative mechanisms involving the $\alpha_v\beta_3$ integrin, osteopontin, and thrombin. *Am. J. Pathol.*, *149*: 293–305, 1996.
28. Liaw, L., Skinner, M. P., Raines, E. W., Ross, R., Cheresch, D. A., Schwartz, S. M., and Giachelli, C. M. The adhesive and migratory effects of osteopontin are mediated via distinct cell surface integrins. *J. Clin. Invest.*, *95*: 713–724, 1995.
29. Hu, D. D., Lin, E. C. K., Kovach, N. L., Hoyer, J. R., and Smith, J. W. A biochemical characterization of the binding of osteopontin to integrins $\alpha_v\beta_1$ and $\alpha_v\beta_3$. *J. Biol. Chem.*, *270*: 26232–26238, 1995.
30. Weber, G. F., Ashkar, S., Glimcher, M. J., and Cantor, H. Receptor-ligand interaction between CD44 and osteopontin (η -1). *Science (Wash. DC)*, *271*: 509–512, 1996.
31. Katagiri, Y. U., Sleeman, J., Fujii, H., Herrlich, P., Hotta, H., Tanaka, K., Chikuma, S., Yagita, H., Okomura, K., Murakami, M., Saiki, I., Chambers, A. F., and Uede, T. CD44 variants but not CD44s cooperate with β 1-containing integrins to permit cells to bind to osteopontin independently of arginine-glycine-aspartic acid, thereby stimulating cell motility and chemotaxis. *Cancer Res.*, *59*: 219–226, 1999.
32. Xuan, J. W., Hota, C., Shigeyama, Y., D'Errico, J. A., Somerman, M. J., and Chambers, A. F. Site-directed mutagenesis of the arginine-glycine-aspartic acid sequence in osteopontin destroys cell adhesion and migration functions. *J. Cell. Biochem.*, *57*: 680–690, 1995.
33. Bautista, D. S., Xuan, J., Hota, C., Chambers, A. F., and Harris, J. F. Inhibition of Arg-Gly-Asp (RGD) mediated cell adhesion to osteopontin by a monoclonal antibody against osteopontin. *J. Biol. Chem.*, *269*: 23280–23285, 1994.
34. Tuck, A. B., Elliott, B. E., Hota, C., Tremblay, E., and Chambers, A. F. Osteopontin-induced, integrin-dependent migration of human mammary epithelial cells involves activation of the hepatocyte growth factor receptor (Met). *J. Cell. Biochem.*, *78*: 465–475, 2000.
35. Brown, L. F., Berse, B., Van de Water, L., Papadopoulos-Sergiou, A., Perruzzi, C. A., Manseau, E. J., Dvorak, H. F., and Senger, D. R. Expression and distribution of osteopontin in human tissues: widespread association with luminal epithelial surfaces. *Mol. Biol. Cell*, *3*: 1169–1180, 1992.
36. Brown, L. F., Papadopoulos-Sergiou, A., Berse, B., Manseau, E. J., Tognazzi, K., Peruzzi, C. A., Dvorak, H. F., and Senger, D. R. Osteopontin expression and distribution in human carcinomas. *Am. J. Pathol.*, *145*: 610–623, 1994.
37. Allred, D. C., Clark, G. M., Elledge, R., Fuqua, S. A. W., Brown, R. W., Chamness, G. C., Osborne, C. K., and McGuire, W. L. Association of p53 protein expression with tumor cell proliferation rate and clinical outcome in node-negative breast cancer. *J. Natl. Cancer Inst. (Bethesda)*, *85*: 200–206, 1993.
38. Maki, M., Hirota, S., Kaneko, Y., and Morohoshi, T. Expression of osteopontin messenger RNA by macrophages in ovarian serous papillary cystadenocarcinoma: a possible association with calcification of psammoma bodies. *Pathol. Int.*, *50*: 531–535, 2000.
39. Singh, R. P., Patarca, R., Schwartz, J., Singh, P., and Kantor, H. Definition of a specific interaction between early T lymphocyte activation 1 (η -1) protein and murine macrophages *in vitro* and its effects upon macrophages *in vivo*. *J. Exp. Med.*, *171*: 1931–1942, 1990.
40. Behrend, E. I., Craig, A. M., Wilson, S. M., Denhardt, D. T., and Chambers, A. F. Expression of antisense osteopontin RNA in metastatic mouse fibroblasts is associated with reduced malignancy. *Ann. N. Y. Acad. Sci.*, *760*: 299–301, 1995.
41. Li, G., Chen, Y. F., Kelpke, S. S., Oparil, S., and Thompson, J. A. Estrogen attenuates integrin- β_3 -dependent adventitial fibroblast migration after inhibition of osteopontin production in vascular smooth muscle cells. *Circulation*, *101*: 2949–2955, 2000.
42. Spencer, T. E., and Bazer, F. W. Biology of progesterone action during pregnancy recognition and maintenance of pregnancy. *Front. Biosci.*, *7*: d1879–d1898, 2002.

Clinical Cancer Research

Correlation of Osteopontin Protein Expression and Pathological Stage across a Wide Variety of Tumor Histologies

Domenico Coppola, Marianna Szabo, David Boulware, et al.

Clin Cancer Res 2004;10:184-190.

Updated version Access the most recent version of this article at:
<http://clincancerres.aacrjournals.org/content/10/1/184>

Cited articles This article cites 42 articles, 12 of which you can access for free at:
<http://clincancerres.aacrjournals.org/content/10/1/184.full#ref-list-1>

Citing articles This article has been cited by 25 HighWire-hosted articles. Access the articles at:
<http://clincancerres.aacrjournals.org/content/10/1/184.full#related-urls>

E-mail alerts [Sign up to receive free email-alerts](#) related to this article or journal.

Reprints and Subscriptions To order reprints of this article or to subscribe to the journal, contact the AACR Publications Department at pubs@aacr.org.

Permissions To request permission to re-use all or part of this article, use this link
<http://clincancerres.aacrjournals.org/content/10/1/184>.
Click on "Request Permissions" which will take you to the Copyright Clearance Center's (CCC) Rightslink site.