

CCR Translations

See related article by Win et al., p. 3591

Predicting Outcome by Images?

Dirk De Ruyscher

Features from CT, MRI, and PET scans are related to survival of patients with non-small cell lung carcinoma. Individualized image-based tissue characterization allows a whole body view of all tumor deposits and organs at risk. The time is ripe to embark on huge international studies aiming to validate and implement this technology in clinical practice. *Clin Cancer Res*; 19(13); 3334–6. ©2013 AACR.

In this issue of *Clinical Cancer Research*, Win and colleagues (1) present data that suggest that tumor characteristics and, more specifically, textural heterogeneity on a CT scan predict survival in patients with non-small cell lung cancer (NSCLC).

The idea to characterize tissues on the basis of imaging is obviously not new. In the early 1980s, attempts were reported aiming at characterizing tissues and tumors to predict response to treatment. The concept is indeed very attractive: With one image, it would be possible to know the prognosis of patients and to predict what the best therapy would be, taking into account the features of the tumor and healthy tissues at risk. Heterogeneity within a tumor or between the primary tumor and its metastases could be defined. Changes over time would be easy to investigate.

However, it became clear that bringing this idea into clinical practice is difficult. Even a seemingly trivial exercise like delineating a tumor mass proved to be difficult to standardize (2). Inter- and intraobserver differences of up to 300% have been reported when no strict standardized protocols were used. A 10% to 30% variability is probably the best that can be achieved with manual tools. It should be emphasized that even these far from optimal results can only be achieved when strictly standardized and validated technical protocols are applied. More recently, national and international organizations have published thorough guidelines for standardization, for example, for CT and positron emission tomography (PET) scans. Thanks to the dramatic improvement in image quality and the availability of fast computers, automated segmentation algorithms have been developed. For CT scans, the selection of ranges of Hounsfield units (which represent the linear attenuation coefficient of the X-ray beam by the tissue) has been used to define tissue types. Calculation of the gradient of an image

can reveal the borders between tissue types. The development of four-dimensional (4D)-CT scans that take into account blurring artifacts due to motion has further improved the accuracy for tissue characterization. It is likely that dual-energy CT and, in the near future, spectral CT will further boost tissue characterization.

At the same time, PET scan technology has moved toward 4D acquisitions and highly standardized procedures as well. PET scans nevertheless suffer from a lower resolution than CT scans, and the information is highly dependent on the tracer that is used. However, a nonspecific but biologically sound tracer such as ^{18}F -deoxyglucose (FDG) has been shown not only to be prognostic for survival in many, though not all series, but also enables the determination of the areas within a single tumor that show differences in sensitivity for radiotherapy (3). Obviously, recent results with PET-labeled drugs such as ^{11}C -docetaxel (4) and ^{11}C -erlotinib (5), a technology that is useful for many interesting small molecules (6), will further enhance the use of PET scans for tumor characterization.

These technical developments have led many research groups to look in more detail at the image characteristics of tumors themselves. In general, texture on CT was quantified as mean gray-level intensity, entropy, and uniformity (7). A relationship between texture features in NSCLC on non-contrast-enhanced CT and tumor metabolism and stage was reported (8). In metastatic renal cell carcinoma treated with sunitinib, cedirinib, pazopanib, or regorafenib, CT texture analysis reflecting tumor heterogeneity was an independent factor associated with time to progression, showing its potential as a predictive imaging biomarker of response (9).

Fine-texture features are associated with poorer 5-year overall survival rate in patients with primary colorectal cancer (10). Entropy, uniformity, kurtosis, skewness, and SD of the pixel distribution histogram were derived from CT images, and each parameter was independent from the stage predictor of overall survival rate.

Qualitative imaging parameters on CT and MRI scans have been used to predict mRNA abundance variation, for example, in brain tumors (11).

The study of Win and colleagues (1) adds further evidence that textural heterogeneity of the tumor indeed is correlated

Author's Affiliation: Department of Radiation Oncology, University Hospitals Leuven/KU Leuven, Leuven, Belgium

Corresponding Author: Dirk De Ruyscher, Department of Radiation Oncology, University Hospitals Leuven/KU Leuven, Herestraat 49, 3000 Leuven, Belgium. Phone: 32-16-347600; Fax: 32-16-347623; E-mail: dirk.deruyscher@uzleuven.be

doi: 10.1158/1078-0432.CCR-13-1114

©2013 American Association for Cancer Research.

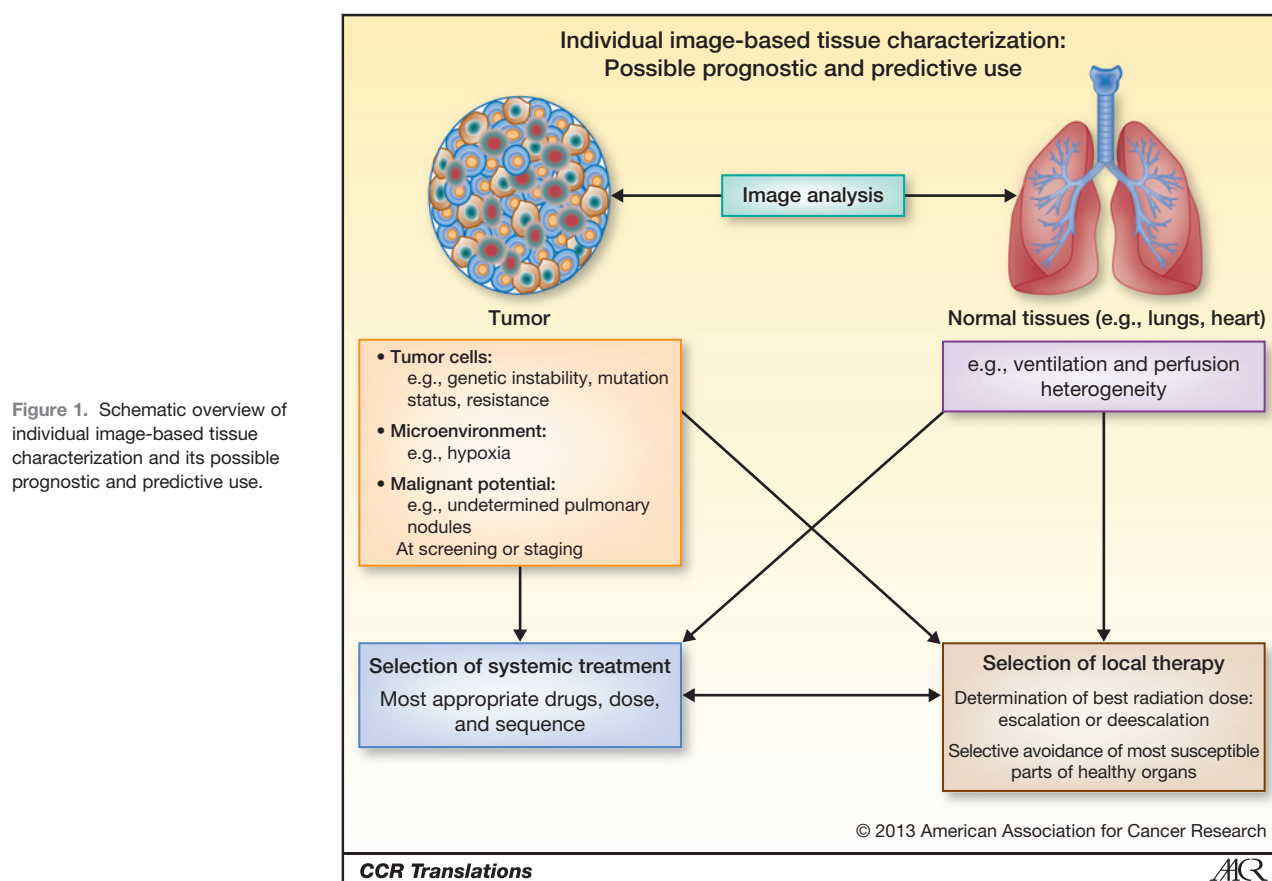


Figure 1. Schematic overview of individual image-based tissue characterization and its possible prognostic and predictive use.

with survival of patients with NSCLC. These investigators built a model for survival in a training set of 56 patients and validated the model in an independent validation cohort consisting of 66 individuals. Textural heterogeneity was prognostic for survival in univariate analysis, whether based on CT or on FDG-PET scans as well as diffusion-enhanced CT measured permeability and stage. The maximal uptake of FDG was not related to survival. In a multivariate analysis, permeability ($P < 0.001$) was the most important survival predictor, followed by stage ($P = 0.001$) and CT textural heterogeneity ($P = 0.021$).

It is conceivable that in the coming years we will witness a growing body of evidence that multidimensional parameters derived from different imaging modalities will be able to characterize tumors. The input may be plain scans; functional imaging, such as perfusion parameters; or molecular imaging. CT, MRI, and PET will surely be complementary. In view of the remarkable heterogeneity among patients, tumors, and metastases and the changes of the tumor and its microenvironment over time, imaging will probably become an essential component for therapy selection, together with other parameters, such as clinical data and molecular signatures from tumor cells or DNA from circulating lymphocytes. It remains to be seen which features are specific for a given tumor or treatment and which are more generic. The latter would obviously simplify

research very much. The ultimate aim of this research should be to create a framework for individualized image-based tissue characterization for prognostic and predictive use (Fig. 1). This should not only include tumor characterization but also take into account the tissues and organs at risk for side effects. Only then can a truly individualized therapeutic ratio be determined. Individualized image-based tissue characterization will be of importance for systemic and local therapy and may even be of interest for screening and staging, for example, for the determination of small nodules. However, a huge international effort is needed to accomplish this goal. Standardization, large databases, and decision-support systems are key, as well as prospective validation of the findings in randomized clinical trials (12).

Current know-how allows this to happen at present. It is the research community, the funding agencies, and companies working together that will be able to address the challenges and tackle them. At the very end, patients and all stakeholders will benefit from this paradigm.

Disclosure of Potential Conflicts of Interest

No potential conflicts of interest were disclosed.

Received May 6, 2013; accepted May 8, 2013; published OnlineFirst May 28, 2013.

References

1. Win T, Miles KA, Janes SM, Ganeshan B, Shastry M, Endozo R, et al. Tumor heterogeneity as measured on the CT component of PET/CT predicts survival in patients with potentially curable non-small cell lung cancer. *Clin Cancer Res* 2013;19:3591-99.
2. van Baardwijk A, Bosmans G, Boersma L, Buijsen J, Wanders S, Hochstenbag M, et al. PET-CT-based auto-contouring in non-small-cell lung cancer correlates with pathology and reduces interobserver variability in the delineation of the primary tumor and involved nodal volumes. *Int J Radiat Oncol Biol Phys* 2007;68:771-8.
3. Petit SF, Aerts HJ, van Loon JG, Offermann C, Houben R, Winkens B, et al. Metabolic control probability in tumour subvolumes or how to guide tumour dose redistribution in non-small cell lung cancer (NSCLC): an exploratory clinical study. *Radiother Oncol* 2009;91:393-8.
4. van der Veldt AA, Lubberink M, Mathijssen RH, Loos W, Herder GJ, Greuter HN, et al. Towards prediction of efficacy of chemotherapy: a proof of concept study in lung cancer patients using [11C]docetaxel and positron emission tomography. *Clin Cancer Res* 2013 Apr 25. [Epub ahead of print].
5. Bahce I, Smit EF, Lubberink M, van der Veldt AA, Yaqub M, Windhorst AD, et al. Development of [(11)C]erlotinib positron emission tomography for *in vivo* evaluation of EGF receptor mutational status. *Clin Cancer Res* 2013;19:183-93.
6. Dingemans AM, Mellema WW, Groen HJ, van Wijk A, Burgers SA, Kunst PW, et al. A phase II study of sorafenib in patients with platinum-pretreated, advanced (Stage IIIb or IV) non-small cell lung cancer with a KRAS mutation. *Clin Cancer Res* 2013;19:743-51.
7. Ganeshan B, Miles KA, Young RC, Chatwin CR. Texture analysis in non-contrast enhanced CT: impact of malignancy on texture in apparently disease-free areas of the liver. *Eur J Radiol* 2009;70:101-10
8. Goh V, Ganeshan B, Nathan P, Juttla JK, Vinayan A, Miles KA. Assessment of response to tyrosine kinase inhibitors in metastatic renal cell cancer: CT texture as a predictive biomarker. *Radiology* 2011;261:165-71.
9. Ganeshan B, Skogen K, Pressney I, Coutroubis D, Miles K. Tumor heterogeneity in oesophageal cancer assessed by CT texture analysis: preliminary evidence of an association with tumour metabolism, stage, and survival. *Clin Radiol* 2012;67:157-64.
10. Ng F, Ganeshan B, Kozarski R, Miles KA, Goh V. Assessment of primary colorectal cancer heterogeneity by using whole-tumor texture analysis: contrast-enhanced CT texture as a biomarker of 5-year survival. *Radiology* 2013;266:177-84.
11. Diehn M, Nardini C, Wang DS, McGovern S, Jayaraman M, Liang Y, et al. Identification of noninvasive imaging surrogates for brain tumor gene-expression modules. *Proc Natl Acad Sci U S A* 2008;105:5213-8
12. Lambin P, van Stiphout RG, Starmans MH, Rios-Velazquez E, Nalbantov G, Aerts HJ, et al. Predicting outcomes in radiation oncology-multifactorial decision support systems. *Nat Rev Clin Oncol* 2013;1:27-40.

Clinical Cancer Research

Predicting Outcome by Images?

Dirk De Ruyscher

Clin Cancer Res 2013;19:3334-3336. Published OnlineFirst May 28, 2013.

Updated version	Access the most recent version of this article at: doi: 10.1158/1078-0432.CCR-13-1114
Supplementary Material	Access the most recent supplemental material at: http://clincancerres.aacrjournals.org/content/suppl/2013/07/01/1078-0432.CCR-13-1114.DC1

Cited articles	This article cites 11 articles, 4 of which you can access for free at: http://clincancerres.aacrjournals.org/content/19/13/3334.full#ref-list-1
-----------------------	---

E-mail alerts	Sign up to receive free email-alerts related to this article or journal.
Reprints and Subscriptions	To order reprints of this article or to subscribe to the journal, contact the AACR Publications Department at pubs@aacr.org .
Permissions	To request permission to re-use all or part of this article, use this link http://clincancerres.aacrjournals.org/content/19/13/3334 . Click on "Request Permissions" which will take you to the Copyright Clearance Center's (CCC) Rightslink site.