

Merkel Cell Carcinomas Arising in Autoimmune Disease Affected Patients Treated with Biologic Drugs, Including Anti-TNF

John Charles Rotondo¹, Ilaria Bononi¹, Andrea Puozzo¹, Marcello Govoni²,
Valentina Foschi², Giovanni Lanza², Roberta Gafà¹, Pauline Gaboriaud³,
Françoise Antoine Touzé³, Rita Selvatici², Fernanda Martini¹, and Mauro Tognon¹



Abstract

Purpose: The purpose of this investigation was to characterize Merkel cell carcinomas (MCC) arisen in patients affected by autoimmune diseases and treated with biologic drugs.

Experimental Design: Serum samples from patients with MCC were analyzed for the presence and titer of antibodies against antigens of the oncogenic Merkel cell polyomavirus (MCPyV). IgG antibodies against the viral oncoproteins large T (LT) and small T (ST) antigens and the viral capsid protein-1 were analyzed by indirect ELISA. Viral antigens were recombinant LT/ST and virus-like particles (VLP), respectively. MCPyV DNA sequences were studied using PCR methods in MCC tissues and in peripheral blood mononuclear cells (PBMC). Immunohistochemical (IHC) analyses were carried out in MCC tissues to reveal MCPyV LT oncoprotein.

Results: MCPyV DNA sequences identified in MCC tissues showed 100% homology with the European MKL-1 strain.

PBMCs from patients tested MCPyV-negative. Viral DNA loads in the three MCC tissues were in the 0.1 to 30 copy/cell range. IgG antibodies against LT/ST were detected in patients 1 and 3, whereas patient 2 did not react to the MCPyV LT/ST antigen. Sera from the three patients with MCC contained IgG antibodies against MCPyV VP1. MCC tissues tested MCPyV LT-antigen-positive in IHC assays, with strong LT expression with diffuse nuclear localization. Normal tissues tested MCPyV LT-negative when employed as control.

Conclusions: We investigated three new MCCs in patients affected by rheumatologic diseases treated with biologic drugs, including TNF. A possible cause-effect relationship between pharmacologic immunosuppressive treatment and MCC onset is suggested. Indeed, MCC is associated with MCPyV LT oncoprotein activity. *Clin Cancer Res*; 23(14); 3929–34. ©2017 AACR.

Introduction

Merkel cell carcinoma (MCC) is a rare but aggressive neuro-endocrine tumor (1). Annual incidence is estimated at about 2.4 and 3/million/year in Europe (2) and the United States (3), respectively, with increased frequency over the last 20 years.

MCC arises more frequently in elderly people, white subjects of both genders predominantly in sun-exposed areas, with the presentation at average onset age of 69 years (4). Its high mortality rate may be partially explained by the advanced onset age, which results in a decrease in immune function, closely related to aging (5). Iatrogenic immunosuppression has been demonstrated to be

a risk factor for MCC development. Immunosuppressed individuals, such as those affected by AIDS, oncologic or hematological diseases, and organ transplant recipients (OTR), represent approximately 10% of MCC-affected patients (4). These MCC immunosuppressed patients have poorer prognoses (6). The role of immunosuppressive therapy in MCC pathogenesis is also suggested by reports of partial spontaneous regression of metastatic MCC after treatment discontinuation (7).

DNA sequences of Merkel cell polyomavirus (MCPyV) were identified in MCC (8). Then, MCPyV sequences were detected in MCC in up to 80% of cases, whereas Ig antibodies against MCPyV were revealed in approximately 80% of healthy subjects and MCC-affected patients. These results indicate that MCPyV, which is potentially oncogenic, is a ubiquitous human virus (9).

The introduction of biologic disease-modifying anti-rheumatic drugs (bDMARD) in treating some rheumatic diseases, such as rheumatoid arthritis and spondyloarthritis, has completely changed the management and outcome of these disorders. Their efficacy has been widely demonstrated in several randomized clinical trials and observational registries. These drugs are able to induce significant clinical improvement, often remission, and may prevent functional disability, as well as slowing or halting radiographic damage progression (10, 11). Their safety profile has globally been demonstrated as satisfactory with a favorable risk/benefit ratio. However, more information about long-term toxicity and harmfulness is necessary to assist clinicians in decision-making and follow-up. Some reviews have reported on this topic

¹Department of Morphology, Surgery and Experimental Medicine, School of Medicine, University of Ferrara, Ferrara, Italy. ²Department of Medical Sciences, School of Medicine, University of Ferrara, Ferrara, Italy. ³Université François Rabelais, UMR INRA 1282 ISP, Faculté des Sciences Pharmaceutiques, Tours, France.

Note: Supplementary data for this article are available at Clinical Cancer Research Online (<http://clincancerres.aacrjournals.org/>).

J.C. Rotondo and I. Bononi contributed equally to this study.

Corresponding Authors: Mauro Tognon, Department of Morphology, Surgery and Experimental Medicine, University of Ferrara, Ferrara 44121, Italy. Phone: 3905-3245-5538; Fax: 3905-3245-5533; E-mail: mauro.tognon@unife.it; and Fernanda Martini, fernanda.martini@unife.it

doi: 10.1158/1078-0432.CCR-16-2899

©2017 American Association for Cancer Research.

Translational Relevance

In this investigation, three new Merkel cell carcinomas (MCC), which arose in patients with rheumatologic diseases treated with biologic drugs, were characterized. A possible cause–effect relationship between pharmacologic immunosuppressive treatment and MCC onset is plausible. Indeed, the association between MCC and MCPyV infection is well-established. It has been reported that biologic drug treatment allows latent viruses to be reactivated. Active viruses, in turn, may exert their tumorigenic potential through viral oncoproteins, such as MCPyV LT/ST. Clinicians/Oncologists should take the possible reactivation of latent viruses with oncogenic potential, such as MCPyV, into consideration. Specific attention should be given to patients treated with biologic drugs that impair immunologic activities. MCPyV reactivation can be detected by determining the presence and titer of IgG antibodies against its antigens. In the case of virus reactivation, treatment with biologic drugs should be withdrawn, thus reducing the risk of MCC onset.

(10, 12) comparing the adverse events of TNF blockers, IL1 antagonist, IL6 antagonist, anti-CD28, and anti-B-cell monoclonal antibodies in the treatment of different rheumatic diseases. Overall, the difference between cancer rates was not statistically significant between patients treated with biologics and the control group not exposed to biologics, with conflicting results for non-melanoma skin cancer (NMSC). In UV-exposed patients, a significantly increased risk of NMSC was reported by Wolfe and colleagues [ref. 13; relative risk (RR), 1.5; 95% confidence interval (CI), 1.2–1.8], in the ARTIS registry (14), in particular in the first year of treatment (RR, 2.1; 95% CI, 0.8–5.1), and in recent systematic reviews and meta-analysis (12, 15). Conversely, a nonsignificant increased risk was found in the CORRONA (<http://www.rheumatology.org/>; 1.83, 95% CI, 0.85–3.93) and in the BSRBR registries (<http://www.rheumatology.org.uk/>; HR, 1.7, 95% CI, 0.9–3.4), whereas a study based on the BIOBADASER registry (16) failed to demonstrate an increased NMSC rate in the population treated with TNF inhibitor (TNFi). Previous skin cancer history, ethnic background, and solar damage are some of the possible factors that could justify the difference in these results. Furthermore, a different risk profile for malignancies according to the specific autoimmune disease and the biologic drug employed in the treatment should be considered. The most common skin neoplasms related to anti-TNF therapy are basal and squamous cell carcinomas, whereas cutaneous lymphomas are rarely reported. However, some studies have described cases of patients with rheumatic disease treated with biologic drugs who have developed MCC (16–18).

Materials and Methods

MCC cases

Three MCC cases, 2 in patients affected by rheumatoid arthritis and 1 in a patient with ankylosing spondylitis, all exposed to biologic drugs, mainly anti-TNF, were studied in detail for clinical features and characterization of MCPyV sequences, antibodies, and viral proteins in their peripheral blood mononuclear cell (PBMC) and MCC specimens. Details of cases are reported in the

Supplementary Data. Written informed consent was obtained from patients at the time of hospital admission. The study was approved by the Ethic Committee of Ferrara.

MCC and PBMC DNA extraction

Total DNA was extracted from MCC, formalin-fixed, paraffin-embedded (FFPE) specimens, belonging to patients ($n = 3$), using the QIAmp DNA FFPE Tissue Extraction Kit (Qiagen), as described (19). Total DNA was extracted from PBMCs belonging to patients ($n = 3$) using QIAmp DNA Blood Mini Kit (Qiagen), as described (20). After DNA extraction, each sample was quantified by the spectrophotometric reading (NanoDrop 2000, Thermo Scientific). DNA was stored at -80°C until the time of the analysis. DNA was evaluated for its PCR suitability by amplifying the β -globin gene sequences (21).

MCPyV DNA detection and sequence analysis

To verify the presence of MCPyV DNA sequences, DNA from MCC and PBMC samples was analyzed by qualitative PCR with MCPyLT1709.F and MCPyLT1846.R primer set, which generate an amplicon of 138 bp (20). The forward and reverse primers are located at nucleotide positions 1,709 to 1,846, based on the GenBank sequence EU375803. The pUC57MC1 recombinant plasmid carrying DNA of the MCC 350 strain was used as a positive control (8). This recombinant plasmid was a kind gift from Dr. Allander, Karolinska Institutet (Stockholm, Sweden). Amplified MCPyV PCR products were purified using the QIAquick PCR Purification Kit (Qiagen) according to the manufacturer's instructions. MCPyV genotype was identified by direct sequence analysis. PCR amplicons were sequenced with automated ABI Prism 3730 \times 1 Genetic Analyser (Applied Biosystems). The resulting MCPyV DNA sequences were BLAST versus MCPyV DNA belonging to different viral strains present in the National Center for Biotechnology Information (NCBI) database (<http://www.ncbi.nlm.nih.gov/blast/Blast.cgi>). Specifically, MCPyV DNA sequences were aligned against the reference sequences of the North America (MCC350, EU375803.1; MCC339, EU375804.1), Japan (TKS, FJ 464337), Sweden, France, and Italy MCPyV isolates (MKL-1, FJ173815; refs. 22, 23).

MCPyV DNA load quantification

Specific quantitative real-time PCR assays, using TaqMan chemistry, were performed using the CFX96 Touch Real-Time PCR Detection System (Bio-Rad) for MCPyV DNA load quantification. Recombinant plasmid pMCPyVLT.1, which contains 258 bp of the large T antigen (24) coding sequence (FJ472933), was used as positive control (25). Standard calibration curves were generated using 10-fold dilutions, from 10^1 to 10^7 copies, of pMCPyVLT.1 (20). Cellular RNase P gene was used to determine the human cell equivalents of each sample under analysis (26). Samples and controls were analyzed in duplicate. The sensitivity of the method was 10 viral copies. Viral DNA loads are reported as MCPyV DNA copy/cell equivalent.

Immunohistochemical analysis

Immunohistochemical (IHC) analysis was performed on the 3 MCC FFPE samples. IHC staining was performed by using the Multimeric Detection Kit [Universal DAB Detection Kit Ultraview, Roche Tissue Diagnostics (CH)], on a BenchMark XT immunostainer (Roche T.D.; ref. 21). FFPE slices, 4- μm -thick, were stained with mouse monoclonal antibody against the MCPyV LT-antigen

Table 1. MCPyV screening in MCCs and PBMC samples by qPCR analysis

Patient	PCR		qPCR	
	MCC	PBMCs	MCC	PBMCs
1	+	–	+	–
2	+	–	+	–
3	+	–	+	–
MCPyV-positive	3/3	0/3	3/3	0/3

(CM2B4; Santa Cruz Biotechnology; dilution, 1:50). Staining intensity and its distribution were assessed by the pathologists of our working group. Staining was graded as negative (no staining) and as weak, moderate, or strong intensity.

Detection of serum IgG antibodies against MCPyV VP1 protein and LT/ST antigens

Serum antibodies against MCPyV viral protein-1 (VP1), large T and small T antigens (LT/ST; ref. 27), were detected by ELISA using MCPyV virus-like particles (VLP) and the recombinant LT/ST. VLPs and LT/ST were generated and purified as previously described (27, 28). Detection of VP1 and LT/ST antibodies by indirect ELISA was performed as previously described (27, 28).

Results

MCPyV genome analysis

MCC ($n = 3$) and PBMC ($n = 3$) samples of patients affected by autoimmune diseases were analyzed by qualitative PCR for the presence of MCPyV DNA, targeting MCPyV LT gene coding sequences. In a previous study, we detected MCPyV DNA sequences in 22% of PBMCs from healthy subjects (20), whereas other groups found MCPyV sequences in PBMCs from patients with MCC (29). Herein, MCPyV DNA was detected in all 3 MCC samples, whereas none of the 3 PBMCs analyzed showed MCPyV DNA sequences (Table 1).

The viral DNA load from the 3 MCPyV-positive MCC samples was evaluated by specific real-time quantitative PCR (qPCR) analysis (Table 2). In the MCC sample from patient 1, the mean MCPyV DNA load was 29.89 copy/cell (range, 18.27–42.68 copy/

Table 2. Mean MCPyV DNA load in MCPyV-positive MCCs revealed by qPCR analysis

Patient	MCPyV DNA Load	
	(copy/cell)	Range (copy/cell)
1	2.989×10^1	1.827×10^1 to 4.268×10^1
2	1.031×10^{-1}	5.054×10^{-2} to 1.483×10^{-1}
3	0.153×10^1	7.0192×10^{-1} to 0.237×10^1
Mean MCPyV DNA load	1.05×10^1	0.634×10^{-1} to 1.566×10^1

NOTE: Viral DNA loads are reported as MCPyV DNA copy/cell equivalent.

cell). In the MCC sample from patient 2, the mean MCPyV DNA load was 0.1 copy/cell (range, 0.05–0.15 copy/cell). In the MCC sample from patient 3, the mean MCPyV DNA load was 1.5 copy/cell (range, 0.7–2.37 copy/cell; Table 2).

To check the specificity of PCR amplicons as obtained in the 3 MCC samples from patients, the amplified products were subjected to DNA sequencing (Fig. 1). DNA sequence data were compared to the reference sequence, shown in Fig. 1A, of the North American (MCC339 strain, gene bank EU375804.1; MCC350 strain, gene bank EU375803.1), European (Sweden, France, and Italy; MKL-1 strain, gene bank FJ173815), and Japanese MCPyV isolates (TKS strain, gene bank FJ 464337). DNA analysis indicated that MCPyV LT coding sequences were identified as belonging to the MCPyV genome in all 3 MCC samples. Specifically, DNA analysis indicated that MCPyV LT sequences were 100% homologous to the European strain MCPyV MKL-1 in all 3 MCC samples (Fig. 1B), as shown before (16).

MCPyV LT-antigen analysis by IHC staining

To evaluate MCPyV LT-antigen protein expression, IHC staining on MCC tissue samples from patients ($n = 3$) was carried out. MCPyV LT-antigen was present in all tissue sections. Specifically, MCPyV LT-antigen was strongly expressed with diffuse nuclear localization (Fig. 2A–C) in MCC tissue samples from patients. In the corresponding normal tissues, MCPyV LT-antigen expression was not detected (Fig. 2D).

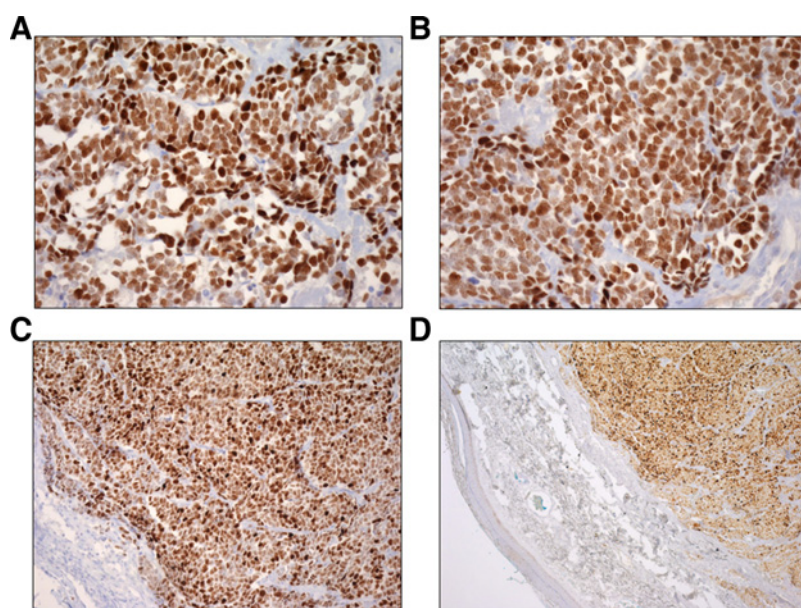
MCPyV antibodies detection by indirect ELISA

Indirect ELISA was carried out to determine the presence of serum antibodies against MCPyV in patients with MCC. Sera from

**Figure 1.**

MCPyV sequence analysis. **A**, Alignment of MCPyV LT sequences of 4 MCPyV genotype strains, MCC339 (GenBank, accession no. EU375804.1), MCC350 (GenBank, accession no. EU375803.1), MKL-1 (GenBank, accession no. FJ173815), and TKS (GenBank, accession no. FJ 464337) is indicated. Nucleotide substitutions in MCPyV strains are numbered and marked in gray. **B**, Alignment of MCPyV LT sequences identified in MCC sample from patients 1, 2, and 3. Nucleotide substitutions in MCPyV strains are marked in gray. The sequence homology of MCPyV genotypes was compared with the BLAST using flat master-slave with identities of the NCBI.

Rotondo et al.

**Figure 2.**

IHC analysis of MCPyV LT in MCC and normal tissues. IHC analysis with anti-MCPyV LT monoclonal antibody confirmed the elevated nuclear expression of this viral oncoprotein LT in MCC tissues from patients 1 (A), 2 (B), and 3 (C). The control represented by the normal epidermis (D), from patient 3, does not demonstrate immunoreactivity.

the 3 patients, who were found to be MCPyV-positive, were analyzed for the presence of IgG antibodies against MCPyV VP1 and LT/ST antigens. Anti-MCPyV VP1 antibodies were detected in all patients, whereas anti-MCPyV LT/ST antibodies were detected in patients 1 and 3. Serum from patient 2 failed to react with the MCPyV LT/ST antigen. Serum samples were diluted from 1:100 to 1:2,048,000 (anti-MCPyV VP1) and from 1:100 to 1:17,714,700 (anti-MCPyV LT/ST) to determine antibody titers. Patient 1 presents anti-MCPyV VP1 and LT/ST endpoint titers of 1:512,000 (optical density, OD: 0.218) and 1:900 (OD: 0.207), respectively. Patient 2 has an anti-MCPyV VP1 endpoint titer of 1:800 (OD: 0.201) and patient 3 presents anti-MCPyV VP1 and LT/ST endpoint titers of 1:128,000 (OD: 0.22) and 1:300 (OD: 0.246), respectively.

Discussion

In this report, we characterized 3 new MCC cases in patients affected by rheumatologic diseases, all of whom had been exposed to biologic drugs, where a possible cause-effect relationship between the pharmacologic immunosuppressive treatment and cancer arisen could be hypothesized. It has been established that MCC onset/progression is linked to MCPyV, and viral LT gene expression promotes tumor onset/progression (8, 30).

In this study, MCPyV LT DNA sequences were detected in all the 3 MCC samples. Our results are in agreement with previous works where approximately 80% of MCCs are associated with MCPyV (8, 30), suggesting that this virus is likely to be the etiology agent of MCC (8, 30). We detected a viral DNA copy/cell ratio within a 0.06 to 1.2 range, which is sufficient to contribute to MCC (31). Molecular analysis of MCPyV LT DNA sequences from the 3 cases showed high homology with previously published MCPyV sequences obtained from MCC specimens. Specifically, we identified the MKL-1 strain, suggesting that this strain is the main MCPyV isolate in Europe (20, 22). Strong MCPyV LT antigen (LTA) expression in IHC, with diffuse nuclear localization, was evaluated in the 3 MCC tissues. These findings support the thesis that MCPyV has an essential role in MCC-genesis (31). It is

interesting to note that the corresponding PBMCs from the same patients tested negative for MCPyV DNA. In this context, it should be recalled that MCPyV DNA in PBMCs, when revealed, is present at low copy number in patients affected by MCC (29), as well as in healthy subjects (20).

We investigated the presence of serum antibodies against MCPyV in samples of the same 3 patients with MCC. Anti-MCPyV VP1 antibodies were detected in all 3 patients, whereas anti-MCPyV LT/ST antibodies were detected in patients 1 and 3. It could be speculated that the absence of LT/ST antibodies in patient 2 is due to the small tumor size.

Previous serologic studies have shown that anti-MCPyV antibodies are present in higher proportions in patients with MCC than in controls (32, 33). Moreover, patients with MCC with high MCPyV antibody titers may present better progression-free survival (34).

Anti-MCPyV antibodies were detected in up to 80% of adults and from 20% to 43% of 1- to 5-year-old children. These data suggest that MCPyV infects a large proportion of the population, where it induces a physiological immune response (28, 32, 33).

The 3 patients with MCC were pharmacologically treated with immunosuppressive biologic drugs due to being affected by rheumatologic diseases. In general, about 10% of MCC cases are detected in immunosuppressed individuals (35), whereas it is well-known that patients with impaired immune functions are more at risk of developing virus-related diseases (36). For instance, immunosuppression induced by HIV/AIDS in HIV-positive individuals increases the risk of developing MCC compared with HIV-negative individuals (37). It is well-established that the immune system counteracts MCPyV infection and associated MCC development. Indeed, MCC regression occurs when immunosuppression therapy is suspended/withdrawn (38).

It is also known that pharmacologic therapies using immunosuppressive agents to prevent organ rejection result in immunodeficiency inducing skin cancer (39), non-melanoma skin cancer (40), and MCC (41).

Reactivation of other human polyomaviruses (HPyV) by pharmacologic immunosuppressants has been observed in cases of

progressive multifocal leukoencephalopathy (PML; ref. 42), due to polyomavirus JC (JCPyV) reactivation during treatment with natalizumab and rituximab for multiple sclerosis (43) and in acute interstitial nephritis and hemorrhagic cystitis development in stem cell transplant recipients caused by BK polyomavirus (BKPyV; ref. 44). All these viruses are acquired during childhood (45), and the development of an immunocompromised state can result in active replication of viruses and disease occurrence. According to the current evidence, screening for polyomavirus infections should be considered before initiating treatment with biologics.

Pharmacologic immunosuppressive therapies also represent an important additional risk factor for MCC development (16–18) when biologic drugs are employed in managing rheumatologic disorders. Other immunosuppressive drugs used in the treatment of acquired factor VIII inhibitor (46), B-cell chronic lymphocytic leukemia (47), relapsing follicular and chronic lymphocytic lymphomas (48, 49) have been found to be associated with MCC.

To the best of our knowledge, in the current literature, there are only anecdotal reports of MCC occurrence in patients treated with biologic drugs, for a total number of 7 patients: 4 patients treated with rituximab, respectively, for acquired factor VIII inhibitor (46), B-cell chronic lymphocytic leukemia (47), relapsing follicular lymphoma (48), and chronic lymphocytic lymphoma (49). The remaining 3 cases are of patients affected by rheumatic diseases, one with long-standing rheumatoid arthritis treated with adalimumab (16), one with etanercept (18), and the last one affected by psoriatic arthritis treated with etanercept (17).

In this study, patient 1 represents the first case of MCC that appeared in a patient treated with abatacept after 5 months of therapy. It is noteworthy that in this patient, there was previous exposure to 2 anti-TNF α drugs (etanercept 10 months and adalimumab 8 months) and to non-bDMARDs. Therefore, the possible consequences of antecedent exposure to other immunosuppressive drugs cannot be ruled out. In patient 2, MCC was diagnosed after 5 years of infliximab therapy; it rapidly grew after the last infusion and then quickly stopped after the withdrawal of the biological drug. Patient 3 developed MCC after 42 months of etanercept therapy.

In our case, the lag time between initial exposure to a biologic (anti-TNF in all case) and MCC occurrence was rather wide, ranging from 23 to 60 months, compared with the 18 to 24 months reported by others (16–18). Advanced age in patients affected by MCC has been reported as a risk factor for the onset/progression of this tumor (4). Indeed, in our study, patients 1 and 3 were 70 years old and patient 2 was 56 years old. Previously, the highest incidence of MCC had been observed in people older than 65 years (3). However, in previous reports of patients affected by rheumatic diseases in whom an MCC did occur after exposition to anti-TNF, only 1 of 3, was older than 70 years (16–18). Nevertheless, advanced age combined with impaired immune function in the elderly seems to be an important risk factor for MCPyV-related MCC (38).

References

1. Toker C. Trabecular carcinoma of the skin. *Arch Dermatol* 1972; 105:107–10.
2. Eisemann N, Waldmann A, Geller AC, Weinstock MA, Volkmer B, Greinert R, et al. Non-melanoma skin cancer incidence and impact of skin cancer screening on incidence. *J Invest Dermatol* 2014;134:43–50.
3. Agelli M, Clegg LX. Epidemiology of primary Merkel cell carcinoma in the United States. *J Am Acad Dermatol* 2003;49:832–41.
4. Smith DF, Messina JL, Perrott R, Berman CG, Reintgen DS, Cruse CW, et al. Clinical approach to neuroendocrine carcinoma of the skin (Merkel cell carcinoma). *Cancer Control* 2000;7:72–83.

Conclusion

In conclusion, immunosuppression due to biologic drug therapies, chiefly anti-TNF, could represent a risk factor for MCC development in rheumatic patients. Our study data, along with previously reported results, may indicate that pharmacologic immunosuppressive therapy with biologics could modify the immune response to MCPyV, thus undermining the outcome for some who resulted positive for MCPyV and increasing the probability of MCC development. In as much as bDMARDs are potent immunosuppressive agents, their use in managing rheumatologic disorders may enhance susceptibility to MCPyV infections, as well as reducing host antitumoral immune response, thus inducing cancer development. Whether the reintroduction of non-biologic immunosuppressants could be a safe option and whether an alternative biologic with different mechanisms could be considered after an adequate period free from cancer still remains an unanswered question. More data, along with better knowledge of MCC pathogenesis, are needed.

Disclosure of Potential Conflicts of Interest

M. Govoni is a consultant/advisory board member for Abbvie, Alfa Wassermann, Bristol-Myers Squibb, Celgene, MSD, and Roche. No potential conflicts of interest were disclosed by the other authors.

Authors' Contributions

Conception and design: J.C. Rotondo, M. Govoni, V. Foschi, F. Martini, M. Tognon

Development of methodology: J.C. Rotondo, I. Bononi, F.A. Touzé, R. Selvatici, M. Tognon

Acquisition of data (provided animals, acquired and managed patients, provided facilities, etc.): J.C. Rotondo, I. Bononi, A. Puozzo, M. Govoni, V. Foschi, G. Lanza, R. Gafa, P. Gaboriaud, F.A. Touzé, R. Selvatici, M. Tognon
Analysis and interpretation of data (e.g., statistical analysis, biostatistics, computational analysis): J.C. Rotondo, I. Bononi, P. Gaboriaud, F.A. Touzé, R. Selvatici, F. Martini, M. Tognon

Writing, review, and/or revision of the manuscript: J.C. Rotondo, M. Govoni, V. Foschi, G. Lanza, F.A. Touzé, F. Martini, M. Tognon

Administrative, technical, or material support (i.e., reporting or organizing data, constructing databases): M. Tognon

Study supervision: M. Govoni, F. Martini, M. Tognon

Acknowledgments

We wish to thank Drs. Eros Magri and Cristina Bosi, University of Ferrara, for their excellent technical assistance in MCC histochemical staining and Dr. Georgia Emma Gili for revising the English edition of this article.

Grant Support

This study has been supported in parts by Associazione Italiana per la Ricerca sul Cancro (AIRC), grant IG16046; Associazione Sammarinese per la Lotta contro le Leucemie e le Emopatie Maligne (ASLEM), grant CFR/2015; LIONS Club International, District 108 TB, Italy, grant UNIFE 2015; and Fondazione Cassa di Risparmio di Cento, grant 2014 (all to M. Tognon).

The costs of publication of this article were defrayed in part by the payment of page charges. This article must therefore be hereby marked *advertisement* in accordance with 18 U.S.C. Section 1734 solely to indicate this fact.

Received November 17, 2016; revised January 17, 2017; accepted January 18, 2017; published OnlineFirst February 7, 2017.

Rotondo et al.

5. Ponnappan S, Ponnappan U. Aging and immune function: molecular mechanisms to interventions. *Antioxid Redox Sign* 2011;14:1551–85.
6. Paulson KG, Iyer JG, Blom A, Warton EM, Sokil M, Yelistratova L, et al. Systemic immune suppression predicts diminished Merkel cell carcinoma-specific survival independent of stage. *J Invest Dermatol* 2013;133:642–6.
7. Muirhead R, Ritchie DM. Partial regression of Merkel cell carcinoma in response to withdrawal of azathioprine in an immunosuppression-induced case of metastatic Merkel cell carcinoma. *Clin Oncol* 2007;19:96.
8. Feng H, Shuda M, Chang Y, Moore PS. Clonal integration of a polyomavirus in human Merkel cell carcinoma. *Science* 2008;319:1096–100.
9. Nicol JT, Robinot R, Carpentier A, Carandina G, Mazzoni E, Tognon M, et al. Age-specific seroprevalences of merkel cell polyomavirus, human polyomaviruses 6, 7, and 9, and trichodysplasia spinulosa-associated polyomavirus. *Clin Vaccine Immunol* 2013;20:363–8.
10. Carmona L, Abasolo L, Descalzo MA, Perez-Zafriilla B, Sellas A, de Abajo F, et al. Cancer in patients with rheumatic diseases exposed to TNF antagonists. *Semin Arthritis Rheum* 2011;41:71–80.
11. Mariette X, Reynolds AV, Emery P. Updated meta-analysis of non-melanoma skin cancer rates reported from prospective observational studies in patients treated with tumour necrosis factor inhibitors. *Ann Rheum Dis* 2012;71:e2.
12. Mariette X, Matucci-Cerinic M, Pavelka K, Taylor P, van Vollenhoven R, Heatley R, et al. Malignancies associated with tumour necrosis factor inhibitors in registries and prospective observational studies: a systematic review and meta-analysis. *Ann Rheum Dis* 2011;70:1895–904.
13. Wolfe F, Michaud K. Biologic treatment of rheumatoid arthritis and the risk of malignancy - Analyses from a large US observational study. *Arthritis Rheum* 2007;56:2886–95.
14. Asklung J, Baecklund E, Granath F, Geborek P, Fore M, Backlin C, et al. Anti-tumour necrosis factor therapy in rheumatoid arthritis and risk of malignant lymphomas: relative risks and time trends in the Swedish Biologics Register. *Ann Rheum Dis* 2009;68:648–53.
15. Asklung J, Fahrback K, Nordstrom B, Ross S, Schmid CH, Symmons D. Cancer risk with tumor necrosis factor alpha (TNF) inhibitors: meta-analysis of randomized controlled trials of adalimumab, etanercept, and infliximab using patient level data. *Pharmacoeconom Drug Saf* 2011;20:119–30.
16. Krishna SM, Kim CN. Merkel cell carcinoma in a patient treated with adalimumab: case report. *Cutis* 2011;87:81–4.
17. de Giorgi V, Benemei S, Grazzini M, Lotti T, Geppetti P. Rapid growth of merkel cell carcinoma during etanercept treatment of psoriatic arthritis: cause or coincidence? *Acta Derm Venereol* 2011;91:354–5.
18. Linn-Rasker SP, van Albada-Kuipers GA, Dubois SV, Janssen K, Zweers PG. Merkel cell carcinoma during treatment with TNF-alpha inhibitors: coincidence or warning? *Ned Tijdschr Geneesk* 2012;156:A4464.
19. Rotondo JC, Borghi A, Selvatici R, Magri E, Bianchini E, Montinari E, et al. Hypermethylation-induced inactivation of the IRF6 gene as a possible early event in progression of vulvar squamous cell carcinoma associated with lichen sclerosus. *JAMA Dermatol* 2016;152:928–33.
20. Pancaldi C, Corazzari V, Maniero S, Mazzoni E, Comar M, Martini F, et al. Merkel cell polyomavirus DNA sequences in the buffy coats of healthy blood donors. *Blood* 2011;117:7099–101.
21. Rotondo JC, Bosi S, Bassi C, Ferracin M, Lanza G, Gafa R, et al. Gene expression changes in progression of cervical neoplasia revealed by microarray analysis of cervical neoplastic keratinocytes. *J Cell Physiol* 2015;230:806–12.
22. Touze A, Gaitan J, Maruani A, Le Bidre E, Doussinaud A, Clavel C, et al. Merkel cell polyomavirus strains in patients with Merkel cell carcinoma. *Emerg Infect Dis* 2009;15:960–2.
23. Katano H, Ito H, Suzuki Y, Nakamura T, Sato Y, Tsuji T, et al. Detection of Merkel cell polyomavirus in Merkel cell carcinoma and Kaposi's Sarcoma. *J Med Virol* 2009;81:1951–8.
24. Yang D, Holt GE, Velders MP, Kwon ED, Kast WM. Murine six-transmembrane epithelial antigen of the prostate, prostate stem cell antigen, and prostate-specific membrane antigen: prostate-specific cell-surface antigens highly expressed in prostate cancer of transgenic adenocarcinoma mouse prostate mice. *Cancer Res* 2001;61:5857–60.
25. Goh S, Lindau C, Tiveljung-Lindell A, Allander T. Merkel cell polyomavirus in respiratory tract secretions. *Emerg Infect Dis* 2009;15:489–91.
26. Pancaldi C, Balatti V, Guaschino R, Vaniglia F, Corallini A, Martini F, et al. Simian virus 40 sequences in blood specimens from healthy individuals of Casale Monferrato, an industrial town with a history of asbestos pollution. *J Infect* 2009;58:53–60.
27. Samimi M, Molet L, Fleury M, Laude H, Carlotti A, Gardair C, et al. Prognostic value of antibodies to Merkel cell polyomavirus T antigens and VP1 protein in patients with Merkel cell carcinoma. *Br J Dermatol* 2016;174:813–22.
28. Touze A, Gaitan J, Arnold F, Cazal R, Fleury MJ, Combelas N, et al. Generation of Merkel cell polyomavirus (MCV)-like particles and their application to detection of MCV antibodies. *J Clin Microbiol* 2010;48:1767–70.
29. Shuda M, Arora R, Kwun HJ, Feng H, Sarid R, Fernandez-Figueras MT, et al. Human Merkel cell polyomavirus infection I. MCV T antigen expression in Merkel cell carcinoma, lymphoid tissues and lymphoid tumors. *Int J Cancer* 2009;125:1243–9.
30. Becker JC, Schrama D, Houben R. Merkel cell carcinoma. *Cell Mol Life Sci* 2009;66:1–8.
31. Bhatia K, Goedert JJ, Modali R, Preiss L, Ayers LW. Merkel cell carcinoma subgroups by Merkel cell polyomavirus DNA relative abundance and oncogene expression. *Int J Cancer* 2010;126:2240–6.
32. Tolstov YL, Pastrana DV, Feng H, Becker JC, Jenkins FJ, Moschos S, et al. Human Merkel cell polyomavirus infection II. MCV is a common human infection that can be detected by conformational capsid epitope immunoassays. *Int J Cancer* 2009;125:1250–6.
33. Carter JJ, Paulson KG, Wipf GC, Miranda D, Madeleine MM, Johnson LG, et al. Association of Merkel cell polyomavirus-specific antibodies with Merkel cell carcinoma. *J Natl Cancer Inst* 2009;101:1510–22.
34. Touze A, Le Bidre E, Laude H, Fleury MJ, Cazal R, Arnold F, et al. High levels of antibodies against merkel cell polyomavirus identify a subset of patients with merkel cell carcinoma with better clinical outcome. *J Clin Oncol* 2011;29:1612–9.
35. Heath M, Jaimes N, Lemos B, Mostaghimi A, Wang LC, Penas PE, et al. Clinical characteristics of Merkel cell carcinoma at diagnosis in 195 patients: the AEIOU features. *J Am Acad Dermatol* 2008;58:375–81.
36. zur Hausen H. The search for infectious causes of human cancers: Where and why. *Virology* 2009;392:1–10.
37. Engels EA, Frisch M, Goedert JJ, Biggar RJ, Miller RW. Merkel cell carcinoma and HIV infection. *Lancet* 2002;359:497–8.
38. Ma JE, Brewer JD. Merkel cell carcinoma in immunosuppressed patients. *Cancers* 2014;6:1328–50.
39. Euvrard S, Ullrich C, Lefrancois N. Immunosuppressants and skin cancer in transplant patients: focus on rapamycin. *Dermatol Surg* 2004;30:628–33.
40. De Luca JF, Severino R, Lee YS, Johnson D. Dermatologist and gastroenterologist awareness of the potential of immunosuppressants used to treat inflammatory bowel disease to cause non-melanoma skin cancer. *Int J Dermatol* 2013;52:955–9.
41. Formica M, Basolo B, Funaro L, Mazzucco G, Segoloni GP, Piccoli G. Merkel cell carcinoma in renal transplant recipient. *Nephron* 1994;68:399.
42. Wiedinger K, Bitsakis C, Chang SL. Reactivation of human polyomaviruses in immunocompromised states. *J Neurovirol* 2014;20:1–8.
43. Carson KR, Focosi D, Major EO, Petrini M, Richey EA, West DP, et al. Monoclonal antibody-associated progressive multifocal leucoencephalopathy in patients treated with rituximab, natalizumab, and efalizumab: a Review from the Research on Adverse Drug Events and Reports (RADAR) Project. *Lancet Oncol* 2009;10:816–24.
44. Dalianis T, Ramqvist T, Andreasson K, Kean JM, Garcea RL. KI, WU and Merkel cell polyomaviruses: a new era for human polyomavirus research. *Semin Cancer Biol* 2009;19:270–5.
45. Kean JM, Rao S, Wang M, Garcea RL. Seroepidemiology of human polyomaviruses. *PLoS Pathog* 2009;5:e1000363.
46. Wirges ML, Saporito F, Smith J. Rapid growth of Merkel cell carcinoma after treatment with rituximab. *J Drugs Dermatol* 2006;5:180–1.
47. Robak E, Biernat W, Krykowski E, Jeziorski A, Robak T. Merkel cell carcinoma in a patient with B-cell chronic lymphocytic leukemia treated with cladribine and rituximab. *Leuk Lymphoma* 2005;46:909–14.
48. Cohen Y, Amir G, Polliack A. Development and rapid dissemination of Merkel-cell carcinomatosis following therapy with fludarabine and rituximab for relapsing follicular lymphoma. *Eur J Haematol* 2002;68:117–9.
49. Papalas JA, McKinney MS, Kulbacki E, Dave SS, Wang E. Merkel cell carcinoma with partial B-cell blastic immunophenotype: a potential mimic of cutaneous richter transformation in a patient with chronic lymphocytic lymphoma. *Am J Dermatopathol* 2014;36:148–52.

Clinical Cancer Research

Merkel Cell Carcinomas Arising in Autoimmune Disease Affected Patients Treated with Biologic Drugs, Including Anti-TNF

John Charles Rotondo, Ilaria Bononi, Andrea Puozzo, et al.

Clin Cancer Res 2017;23:3929-3934. Published OnlineFirst February 7, 2017.

Updated version Access the most recent version of this article at:
doi:[10.1158/1078-0432.CCR-16-2899](https://doi.org/10.1158/1078-0432.CCR-16-2899)

Supplementary Material Access the most recent supplemental material at:
<http://clincancerres.aacrjournals.org/content/suppl/2017/02/07/1078-0432.CCR-16-2899.DC1>

Cited articles This article cites 49 articles, 9 of which you can access for free at:
<http://clincancerres.aacrjournals.org/content/23/14/3929.full#ref-list-1>

E-mail alerts [Sign up to receive free email-alerts](#) related to this article or journal.

Reprints and Subscriptions To order reprints of this article or to subscribe to the journal, contact the AACR Publications Department at pubs@aacr.org.

Permissions To request permission to re-use all or part of this article, use this link
<http://clincancerres.aacrjournals.org/content/23/14/3929>.
Click on "Request Permissions" which will take you to the Copyright Clearance Center's (CCC) Rightslink site.