

*Advances in Brief***Receptor for Interleukin 13 Is a Marker and Therapeutic Target for Human High-Grade Gliomas<sup>1</sup>**

Waldemar Debinski,<sup>2</sup> Denise M. Gibo,  
Stanley W. Hulet, James R. Connor, and  
G. Yancey Gillespie

Section of Neurosurgery, Department of Surgery [W. D., D. M. G.], and Department of Neuroscience and Anatomy [S. W. H., J. R. C.], Pennsylvania State University College of Medicine, Hershey, Pennsylvania 17033-0850; and Division of Neurosurgery, Department of Surgery, The University of Alabama at Birmingham School of Medicine, Birmingham, Alabama 35294-0006 [G. Y. G.]

**Abstract**

**Glioblastoma multiforme (GBM) is an incurable brain tumor. Due to the striking heterogeneity that characterizes GBM, there is no known tumor-specific antigen or receptor that is expressed by a majority of GBM patients. We found that virtually all studied human GBM specimens (23 samples) abundantly expressed a receptor for interleukin (IL)-13 *in situ*, whereas normal human brain had few, if any, IL-13-binding sites. The GBM-associated IL-13 receptor was both quantitatively and qualitatively different from and, thus, more restrictive than the shared signaling receptor of normal tissue: it was IL-4 independent. The receptor for IL-13 was overexpressed by a majority of cancer cells *in situ*. Furthermore, cytotoxins targeted to this more restrictive IL-13R produced cures in animals bearing xenografts of human high-grade gliomas. Thus, unexpectedly, the receptor for an immune regulatory cytokine may be a long sought marker and, concomitantly, a unique imaging site and therapeutic target for GBM, the most malignant and the most heterogeneous of brain tumors.**

**Introduction**

GBM<sup>3</sup> is a rapidly progressive human high-grade glioma for which no effective treatment is available, and the incidence

of brain tumors is on the rise (1, 2). It has been a continuous and, so far, unsuccessful challenge to uncover a receptor for a growth factor/cytokine or an antigen that is not present in normal tissues to any significant degree but is present in >50% of patients with high-grade gliomas, such as GBM. Due to the morphological heterogeneity of GBM tumors, it seemed exceedingly difficult to identify such a potential diagnostic, imaging, therapeutic target receptor, or antigen.

We previously found large amounts of a receptor for IL-13 on a majority of the established human malignant glioma cell lines studied (3) and on cells cultured from freshly resected GBM (4). IL-13 regulates immune responses in a similar manner to its homologue, IL-4 (5, 6), and shares a functional signaling IL-13R/IL-4R that is present on selected normal tissues and is overexpressed on some adenocarcinomas (7–9).

The potential importance of a cancer-associated receptor/antigen depends exclusively on its tumor representation *versus* expression in normal tissue *in situ*. It is noteworthy that recent studies on GBM showed either that a clinically present antigen of high specificity is completely lost in cell culture (10) or that, in a reverse scenario, overexpression of an intracellular molecule seen *in vitro* does not correspond to an *in situ* situation (11). Therefore, the demonstration of the presence of hIL-13 binding sites in GBM and the absence of them on normal brain tissues, using freshly preserved surgical specimens, was essential in substantiating a possible clinical importance of the *in vitro*-detected candidate marker/target (3). This work demonstrates an unexpected discovery of an extraordinarily rich presence of the IL-13R in human GBM but not in normal brain.

**Materials and Methods****Production and Purification of Recombinant Proteins.**

*Escherichia coli* BL21 (λDE3) cells were transformed with plasmids of interest and cultured in Terrific Broth (Difco Laboratories, Detroit, MI). Procedures for recombinant proteins isolation and purification have been described previously (3, 7, 12).

**Autoradiography.** Recombinant hIL-13 (7) was labeled with <sup>125</sup>I by using the Iodo-Gen reagent (Pierce Chemical Co., Rockford, IL) according to the manufacturer's instructions. The specific activity of <sup>125</sup>I-hIL-13 ranged from 40 to 852 μCi/μg of protein. Six different batches of labeled hIL-13 were used in this study. All studies involving human specimens were approved by the respective Human Subjects Protection Offices at the Penn State College of Medicine (Protocol No. IRB 96–123EP) and University of Alabama Medical School. Normal human brain tissues were obtained either from lobectomies and snap-frozen for analysis or they were obtained postmortem from the Harvard Brain Tissue Research Center. GBM tumor samples were obtained from the operating rooms in Penn State College of Medicine and University of Alabama Medical School. Among the 23 patients evaluated, there were 12 females and 11 males, varying in age from 16 to 79 years. The GBMs obtained from a

Received 10/14/98; revised 1/7/99; accepted 2/22/99.

The costs of publication of this article were defrayed in part by the payment of page charges. This article must therefore be hereby marked *advertisement* in accordance with 18 U.S.C. Section 1734 solely to indicate this fact.

<sup>1</sup> This work was supported by the Four Diamonds Fund Grant, Surgery Feasibility Grant, and NIH Grant R01 CA74145 (to W. D.). This work was presented in preliminary forms at the Second Annual Scientific Meeting of the Society for Neuro-Oncology, held October 31–November 2, 1997 in Charlottesville, VA, and at the 17th International Cancer Congress, held August 23–28, 1998, in Rio de Janeiro, Brazil.

<sup>2</sup> To whom requests for reprints should be addressed, at Section of Neurosurgery/H110, Department of Surgery, Pennsylvania State University College of Medicine, 500 University Drive, Hershey, PA 17033-0850. Phone: (717) 531-4541; Fax: (717) 531-5906; E-mail: wdebinski@psghs.edu.

<sup>3</sup> The abbreviations used are: GBM, glioblastoma multiforme; IL, interleukin; hIL-13 and -4, human IL-13 and -4, respectively; IL-13R and IL-4R, IL-13 and -4 receptor, respectively; Tf, transferrin; i.t., intratumoral; CTX, cytotoxin; HUVEC, human umbilical vein endothelial cell.

3-month-old and a 1-year-old, GBM 10 and GBM 22, respectively, were not included in this study. GBM 3 was diagnosed histopathologically as GBM/oligodendroglioma.

The GBMs were processed randomly from among the samples preserved at University of Alabama Medical School or sequentially from among the samples obtained at Penn State College of Medicine. Serial tissue sections were cut (10  $\mu$ m) on a cryostat, thaw-mounted on chrome-alum coated slides, and stored at 4°C until analysis (13). To observe binding distribution of  $^{125}$ I-hIL-13, we incubated sections (1 h, 22°C) with 1.0 nM  $^{125}$ I-hIL-13 in binding buffer (200 mM sucrose, 50 mM HEPES, 1% BSA, and 10 mM EDTA). Adjacent serial sections were incubated with the radiolabeled recombinant hIL-13 after a 30-min preincubation at 22°C in the presence of binding buffer alone or of a 100–500-fold molar excess of unlabeled hIL-13 or hIL-4 or Tf. To dissociate nonspecifically bound radioligand, we rinsed sections in four consecutive changes (5 min each) of ice-cold 0.1 M PBS. At least two sections of each of the tissue specimens were assayed for the evaluation of  $^{125}$ I-hIL-13 binding specificity. After drying, labeled sections were apposed to Kodak autoradiography film at –65°C for 8 h to 11 days.

Autoradiographic images were scanned using HP ScanJet 4C flat-bed scanner (Hewlett-Packard, Boise, ID) at 200 dpi. Sections were analyzed and mounted using the Paint Shop Pro 5 program (Jasc Software, Minnetonka, MN).

Some autoradiographic sections were coated with autoradiography type NTB3 emulsion (Eastman Kodak Co., New Haven, CT) and exposed for 3–4 days in sealed light-tight boxes at 4°C. The preparation was then developed for 5 min with D19 Kodak, rinsing in distilled water for 2 min, fixed in Kodak fixer for 4 min, and washed in distilled water for 2 min. Subsequently, the sections were stained with H&E and analyzed under a light microscope ( $\times 10$  or  $\times 20$  magnification) for the presence of silver grains or using epifluorescence optics.

**Antitumor Experiments.** The human malignant glioma U-373 MG or U-251 MG cells ( $6 \times 10^6$  per mouse) were implanted s.c. into female *nu/nu* athymic mice (5–6-week old) on day 0. The treatment (four to five mice per group) was started when large established tumors were formed, and they were measured with a caliper. The formula for tumor volume calculation was length  $\times$  (width) $^2 \times 0.4$ . The Institutional Animal Care Committee at the Penn State College of Medicine has approved the protocol.

The intracranial model of glioma was as follows: CB-1.7 severe combined immunodeficiency mice were placed in a stereotactic frame and injected with  $1 \times 10^6$  U-251 MG cells in a volume of 5  $\mu$ l using a Hamilton syringe under anesthesia. At 12 and 20 days after tumors were induced, mice received an i.t. injection of either 200 ng of hIL-13-PE4E per mouse or PBS (10 mice per group, 5- $\mu$ l volume). Mice that became moribund or lost >25% of their body weight were killed. Median survivals were computed by Kaplan-Meier analysis. The Institutional Animal Care Committee at the University of Alabama at Birmingham approved the protocol.

## Results

To demonstrate the presence of IL-13-binding sites in clinical specimens *in situ*, we performed autoradiography with

radiolabeled recombinant hIL-13 (Fig. 1, A–C). Twenty-two of 23 adolescent/adult GBMs studied bound  $^{125}$ I-hIL-13, and an excess of unlabeled hIL-13 competed for the binding in all these tumor specimens. The GBM tissues generally labeled densely and homogeneously for  $^{125}$ I-hIL-13-binding sites (Fig. 1, A–C). An excess of recombinant hIL-4 was largely without influence on the  $^{125}$ I-hIL-13 binding to the specimens (Fig. 1, A–C). This is in line with our *in vitro* observations of a hIL-4-independent GBM-associated hIL-13R (3, 4), and it demonstrates that the clinical GBM-associated hIL-13R is different from the functional hIL-13R/hIL-4R (8, 9) of normal tissue. The GBM specimen 6 (Fig. 1A) bound  $^{125}$ I-hIL-13, but its binding was competed for by a cold competitor over the limited area of the section. Only GBM 20 did not show any uptake of the isotope.<sup>4</sup> GBMs 11 (Fig. 1C) and 15<sup>4</sup> had relatively lower binding of hIL-13 when compared with other GBMs, but it was specific for hIL-13 and not for hIL-4.

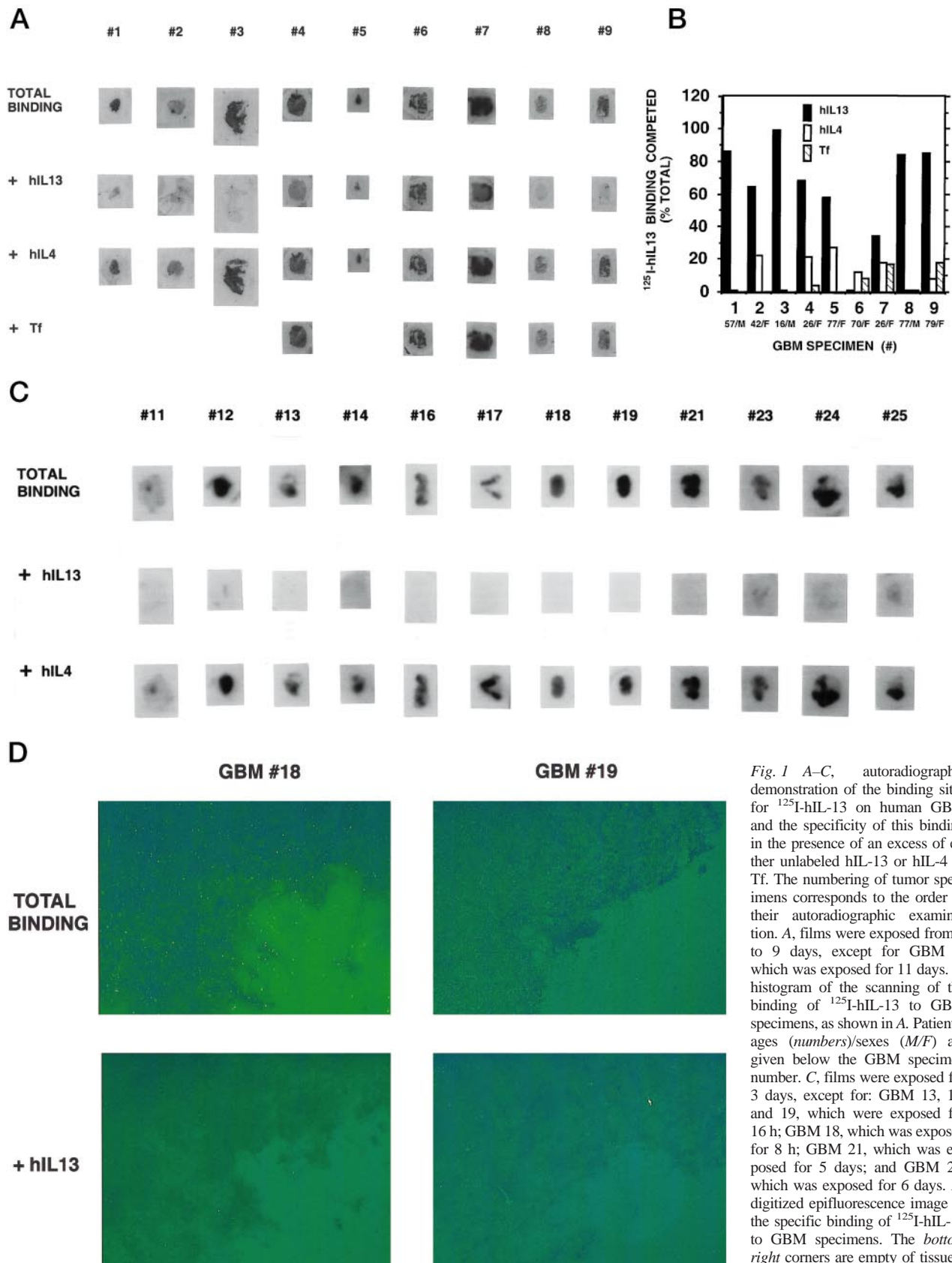
In another test of specificity of the hIL-13 binding to GBM, we used Tf in an attempt to displace the binding of radiolabeled IL (Fig. 1, A and B). We did not observe cross-competition of Tf with the hIL-13-binding sites in the five GBMs examined (Fig. 1, A and B). Thus, the autoradiographic analysis revealed an extraordinary high number of GBMs that express abundantly the more restrictive, IL-4-independent binding sites for IL-13. In another set of experiments and test of specificity, GBM did not exhibit any measurable overexpression of the receptor for hIL-4.<sup>4</sup>

To visualize the areas of GBM sections that bind the labeled hIL-13, we examined the autoradiograms by light microscopy and with epifluorescence optics. As seen in Fig. 1D,  $^{125}$ I-hIL-13-specific binding was distributed relatively uniformly over the whole area of the GBM specimens. Light microscopic analysis revealed that the vast majority of tumor cells was stained with silver grains.<sup>4</sup> This strongly supports the notion that majority of GBM cells possess this more restrictive IL-13R *in situ*.

Because only 1 of the 23 evaluated adolescent/adult GBMs lacked  $^{125}$ I-hIL-13 binding and few more had relatively heterogeneous binding, we analyzed H&E-stained sections that corresponded to all of the autoradiographic images.<sup>4</sup> Those areas of the GBM samples that did not show specific binding of  $^{125}$ I-hIL-13 or that demonstrated more heterogeneous binding were completely (*e.g.*, GBM 20) or partially (*e.g.*, GBM 6) acellular/necrotic. The GBM specimens that bound  $^{125}$ I-hIL-13 avidly had the tumor cellular organization preserved. Thus, it is plausible that all GBMs overexpress hIL-13R. In preliminary studies, other types of brain tumors, including lower-grade gliomas, meningiomas, and medulloblastomas, did not demonstrate this pattern of hIL-13 binding to GBM.<sup>4</sup>

In sharp contrast to the results obtained in GBM, none of the normal human brain tissue samples did reveal appreciable affinity for  $^{125}$ I-hIL-13 (six specimens are shown in Fig. 2). All of the examined specimens showed the same low retention of the  $^{125}$ I-hIL-13 when compared with the labeling of

<sup>4</sup> W. Debinski, D. M. Gibo, B. Slagle, S. K. Poners, and G. Y. Gillespie, unpublished data.



*Fig. 1 A-C,* autoradiographic demonstration of the binding sites for <sup>125</sup>I-hIL-13 on human GBM and the specificity of this binding in the presence of an excess of either unlabeled hIL-13 or hIL-4 or Tf. The numbering of tumor specimens corresponds to the order of their autoradiographic examination. *A,* films were exposed from 7 to 9 days, except for GBM 7, which was exposed for 11 days. *B,* histogram of the scanning of the binding of <sup>125</sup>I-hIL-13 to GBM specimens, as shown in *A*. Patients' ages (*numbers*)/sexes (*M/F*) are given below the GBM specimen number. *C,* films were exposed for 3 days, except for: GBM 13, 16, and 19, which were exposed for 16 h; GBM 18, which was exposed for 8 h; GBM 21, which was exposed for 5 days; and GBM 23, which was exposed for 6 days. *D,* digitized epifluorescence image of the specific binding of <sup>125</sup>I-hIL-13 to GBM specimens. The *bottom right* corners are empty of tissue.

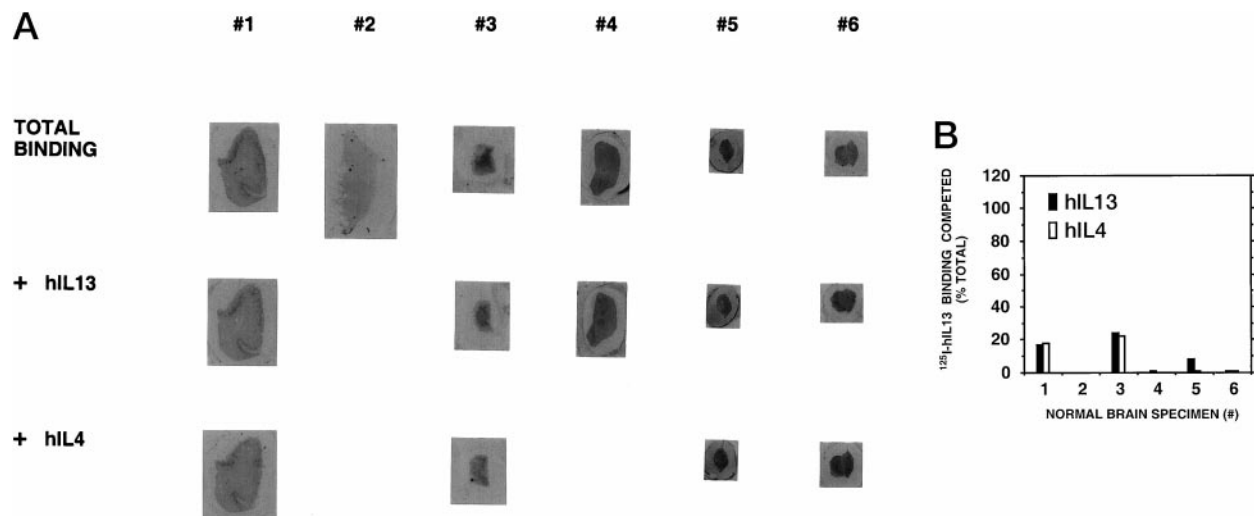


Fig. 2 A, autoradiographic demonstration of the  $^{125}\text{I}$ -hIL-13 binding to normal human brain tissues. Tissue specimens 3, 5, and 6 were obtained from the operating room and the remaining samples were obtained postmortem. #1, motor cortex; #2, white matter; #3, hippocampus; #4, subventricular white matter; #5, temporal lobe; #6, temporal lobe. Films were exposed from 7 to 11 days. B, histogram of the scanning of the binding of  $^{125}\text{I}$ -hIL-13 to normal brain tissues, as shown in A.

GBM, and this low-level binding was changed only marginally, if any, in the presence of an excess of either hIL-13 or hIL-4 (Fig. 2). Overexposed films confirmed the same pattern.<sup>4</sup> These results provide more evidence that the IL-4-independent hIL-13R that we have detected on GBM is absent or is at negligible levels in normal brain and, thus, is a tumor-specific marker. This is in line with the lack of or negligible effect of the hIL-13-based CTX on normal cells, such as HUVECs (12, 14). A similar lack of susceptibility to a hIL-13-CTX was seen in freshly cultured mixed glial cells.<sup>4</sup> Not surprisingly, however, a CTX that targets Tf receptor did kill HUVECs potently at an  $\text{IC}_{50}$  of  $<10$  ng/ml. This is in a range of killing potency of the anti-Tf receptor-CTX observed on some glioma cells *in vitro*. Normal endothelial cells contribute significantly to the strong autoradiographic picture of Tf-binding sites within normal brain (15). The IL-4-CTX also potently killed HUVECs ( $\text{IC}_{50}$  of  $\sim 25$  ng/ml), which is in line with at least two orders of magnitude higher affinity of IL-4 toward the hIL-13R/hIL-4R, compared with IL-13 (16).

In addition to the diagnostic and/or imaging importance of our findings, we explored their relevance to therapeutic applications. We showed that a CTX that targets the hIL-13R could produce dramatic antitumor effects *in vivo*. We used i.t. injections of the CTX because: (a) i.t. delivery has recently been shown to be a promising approach in the treatment of central nervous system malignancy (17–19) and (b) the s.c. model of GBM in mice was predictive of good clinical responses using targeted CTXs (18, 20). Because IL-13, unlike IL-4, is not species specific, the mouse model chosen in this study is even more representative of a clinical situation. We treated mice bearing established s.c. xenografts of U-373 MG glioma with either the vehicle or a hIL-13-CTX (Fig. 3A). The treatment started on day 80 post-tumor implantation when the tumors were  $\sim 200$  mm in size ( $8 \times 8 \times 8$  mm). We found that five i.t.

injections of  $0.5 \mu\text{g}$  of the hIL-13-CTX every other day produced complete regression of the U-373 MG tumors in all of the CTX-treated mice with no signs of toxicity, and one mouse remained free of tumor in the  $0.1\text{-}\mu\text{g}$  CTX-treated group (Fig. 3A). In a faster growing U-251 MG tumor model, when similar in size to U-373 MG tumors were detected on day 30, six i.t. injections of  $0.5 \mu\text{g}$  of the CTX every other day cured (100 days tumor free) 60% of treated mice.<sup>4</sup> Significantly, the treatment of established intracranial U-251 MG tumors resulted in a highly significant prolongation of the survival of mice, and  $>40\%$  of the mice were cured (Fig. 3B).

## Discussion

The main finding of this study is that all nonnecrotic/well-preserved surgical specimens of human GBMs overexpressed specific binding sites for  $^{125}\text{I}$ -hIL-13 *in situ*, whereas normal human brain tissue sections did not. Significantly,  $^{125}\text{I}$ -hIL-13 binding to brain tumor tissues was not blocked with hIL-4. This ascertains that the GBM-associated hIL-13R is different from the functional IL-13R/IL-4R expressed by some normal hemopoietic and somatic cells (8, 9). The tumor-associated hIL-13R appears to be stable and abundantly expressed in GBM because both explant cells (4) and established tumor cell lines (3, 4) exhibit significant levels of the receptor. This offers a unique experimental scenario in which a receptor that is overexpressed *in vitro* corresponds to the frequency and form of the receptor that is found clinically. The expression of an IL-4-independent hIL-13R by GBM cells has been shown by us to be of significance for further translation of this finding into clinical applications (12, 14). Furthermore, the hIL-13-based CTX showed curative activities in both s.c. and intracranial models of human glioma. Thus, a profound effect of the glioma cells environment on their biological behavior (21) did not largely influence the outcome of therapy with a hIL-13 CTX.



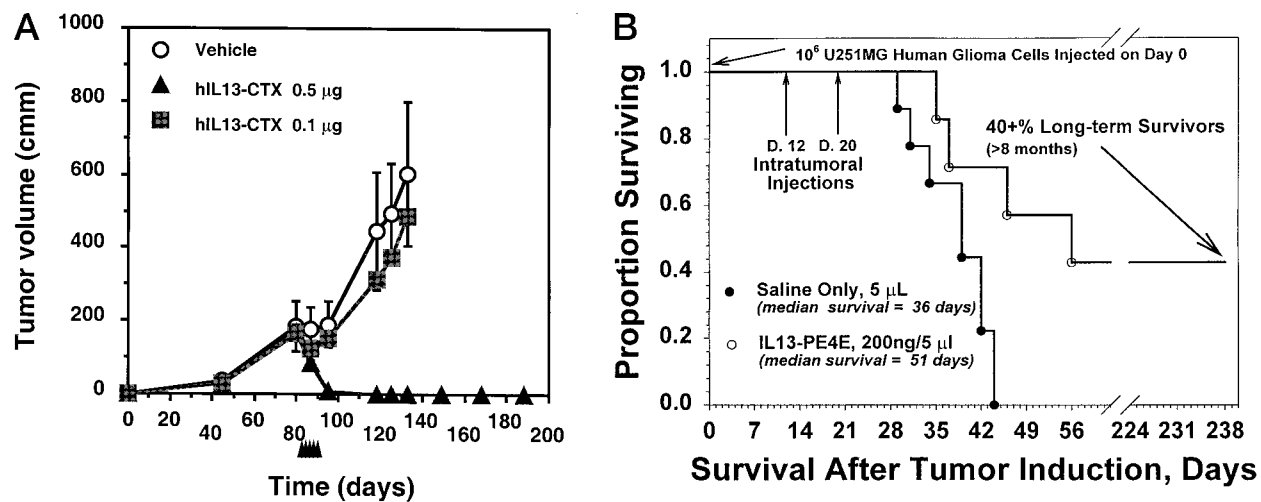


Fig. 3 Antitumor activity of a hIL-13-CTX on s.c. human xenografts of the U-373 MG glioma tumors growing in athymic mice (A) and intracranial human xenografts of the U-251 glioma tumors growing intracranially in severe combined immunodeficiency mice (B). Arrowheads (A), days of either vehicle (PBS-0.1% BSA) or CTX injections at 0.1 and 0.5  $\mu$ g per mouse in a final volume of 25  $\mu$ L. Data points, tumor volumes calculated for four to five mice per group; bars, SEs. The vehicle-treated animals were sacrificed due to the large tumor burden.

It is intriguing that an immune regulatory cytokine receptor is so richly represented in GBM. This linkage between transformation of brain glial cells, the cells believed to be the origin of GBM, and expression of an anti-inflammatory cytokine receptor is unclear at present. However, it has been amply shown that normal glial cells can function in an immune-related capacity in the central nervous system (22). Moreover, a growing body of evidence clearly demonstrates that a wide variety of immune-related cytokines and their cognate receptors are expressed to some extent by human malignant glioma cells (23, 24).

In summary, the GBM-associated hIL-13R represents a unique new marker for diagnostic labeling of cells and potentially for imaging and a target for delivery of cytotoxic or cytostatic therapies to this most devastating malignancy. Our study supports the idea that a malignancy as heterogeneous as glioma could, indeed, be characterized by the expression of specific molecules (25–27). Further investigations based on the knowledge of those molecules should help also in deciphering the pathogenesis of GBM.

### Acknowledgments

We thank all the neurosurgeons in the Section of Neurosurgery at Pennsylvania State University College of Medicine who helped to secure tumor samples (Drs. Holmes, Johnson, Lehman, Page, Powers, and Sumas) and at University of Alabama at Birmingham (Drs. Morawetz, Guthrie, and Markert). We thank Dr. Javad Towfighi of the Department of Pathology for help with examination of the human tissue sections. We are grateful to Dr. Tika Benveniste for reviewing the manuscript. We also thank Dr. Raj K. Puri for labeling our recombinant hIL-13 used in the initial experiments and Dr. Jeffrey P. Thompson and Aynsley Kealisher for reading the manuscript. We thank Dr. Thompson and Sharon L. Menzies for help in figure preparation.

### References

1. Davis, F. G., Freels, S., Grutsch, J., Barlas, S., and Brem, S. Survival rates in patients with primary malignant brain tumors stratified by

patient age and tumor histological type: an analysis based on Surveillance, Epidemiology, and End Results (SEER) data, 1973–1991. *J. Neurosurg.*, 88: 1–10, 1998.

2. Reports from the front. *Science* (Washington DC), 267: 1414, 1995.

3. Debinski, W., Obiri, N. I., Powers, S. K., Pastan, I., and Puri, R. K. Human glioma cells over-express receptor for interleukin 13 and are extremely sensitive to a novel chimeric protein composed of interleukin 13 and *Pseudomonas* exotoxin. *Clin. Cancer Res.*, 1: 1253–1258, 1995.

4. Debinski, W., Miner, R., Leland, P., Obiri, N. I., and Puri, R. K. Receptor for IL13 does not interact with IL4 but receptor for IL4 interacts with IL13 on human glioma cells. *J. Biol. Chem.*, 271: 22428–22433, 1996.

5. McKenzie, A. N. J., Culpepper, J. A., De Waal Malefyt, R., Briere, F., Punnonen, J., Aversa, G., Sato, A., Dang, W., Cocks, B. G., Menon, S., De Vries, J. E., Banchereau, J., and Zurawski, G. Interleukin 13, a T-cell-derived cytokine that regulates human monocyte and B-cell function. *Nat. Acad. Sci. USA*, 90: 3735–3739, 1993.

6. Minty, A., Chalon, P., Derocq, J. M., Dumont, X., Guillemot, J. C., Kaghad, M., Labit, C., Leplat, P., Liauzon, P., Miloux, B., Minty, C., Casellas, P., Loison, G., Lupker, J., Shire, D., Ferrara, P., and Caput, D. Interleukin-13 is a new human lymphokine regulating inflammatory and immune responses. *Nature (Lond.)*, 362: 248–251, 1993.

7. Debinski, W., Obiri, N. I., Pastan, I., and Puri, R. K. A novel chimeric protein composed of interleukin 13 and *Pseudomonas* exotoxin is highly cytotoxic to human carcinoma cells expressing receptors for interleukin 13 and interleukin 4. *J. Biol. Chem.*, 270: 16775–16780, 1995.

8. Murata, T., Obiri, N. I., Debinski, W., and Puri, R. K. Structure of IL-13 receptor: analysis of subunit composition in cancer and immune cells. *Biochem. Biophys. Res. Commun.*, 238: 92–94, 1997.

9. Obiri, N. I., Leland, P., Murata, T., Debinski, W., and Puri, R. K. The IL-13 receptor structure differs on various cell types and may share more than one component with IL-4 receptor. *J. Immunol.*, 158: 756–764, 1997.

10. Lorimer, I. A. J., Wikstrand, C. J., Batra, S. K., Bigner, D. D., and Pastan, I. Immunotoxins that target an oncogenic mutant epidermal growth factor receptor expressed in human tumors. *Clin. Cancer Res.*, 1: 859–864, 1995.

11. Zellner, A., Fetell, M. R., Bruce, J. N., De Vivo, D. C., and O'Driscoll, K. R. Disparity in expression of protein kinase C  $\alpha$  in human glioma versus glioma-derived primary cell lines: therapeutic implications. *Clin. Cancer Res.*, 4: 1797–1802, 1998.

12. Debinski, W., Gibo, D. M., Obiri, N. I., Kealiher, A., and Puri, R. K. Novel anti-brain tumor cytotoxins specific for cancer cells. *Nat. Biotechnol.*, *16*: 449–453, 1998.
13. Hulet, S. W., Hess, E., Debinski, W., Arosio, P., Bruce, K., Powers, S. K., and Connor, J. R. Characterization and distribution of ferritin receptors in the mouse brain. *J. Neurochem.*, *72*: 868–874, 1999.
14. Debinski, W., Gibo, D. M., and Puri, R. K. Novel way to increase targeting specificity to a human glioblastoma-associated receptor for interleukin 13. *Int. J. Cancer*, *76*: 547–551, 1998.
15. Jefferies, W. A., Brandon, M. R., Hunt, S. V., Williams, A. F., Gatter, K. C., and Mason, D. Y. Transferrin receptor on endothelium of brain capillaries. *Nature (Lond.)*, *312*: 162–163, 1984.
16. Zurawski, S. M., Vega, F., Jr., Huyghe, B., and Zurawski, G. Receptors for interleukin-13 and interleukin-4 are complex and share a novel component that functions in signal transduction. *EMBO J.*, *12*: 2663–2670, 1993.
17. Youle, R. J. Immunotoxins for central nervous system malignancy. *Semin. Cancer Biol.*, *7*: 65–70, 1996.
18. Laske, D. W., Youle, R. J., and Oldfield, E. H. Tumor regression with regional distribution of the targeted toxin TF-CRM107 in patients with malignant brain tumors. *Nat. Med.*, *3*: 1362–1368, 1997.
19. Wersall, P., Ohlsson, I., Biberfeld, P., Collins, V., von Krusenstjerna, Larsson, S., Mellstedt, H., and Boethius, J. Intratumoral infusion of the monoclonal antibody, mAb 425, against the epidermal-growth-factor receptor in patients with advanced malignant glioma. *Cancer Immunol. Immunother.*, *44*: 157–164, 1997.
20. Laske, D. W., Ilercil, O., Akbasak, A., Youle, R. J., and Oldfield, E. H. Efficacy of direct intratumoral therapy with targeted protein toxins for solid human gliomas in nude mice. *J. Neurosurg.*, *80*: 520–526, 1994.
21. Gladson, C. L., Wilcox, J. N., Sanders, L., Gillespie, G. Y., and Cheresch, D. A. Cerebral microenvironment influences expression of the vitronectin gene in astrocytic tumors. *J. Cell Sci.*, *108*: 947–956, 1995.
22. Shrikant, P., and Benveniste, T. The central nervous system as an immunocompetent organ. *J. Immunol.*, *157*: 1819–1822, 1996.
23. VanMeir, E. G. Cytokines and the tumors of the central nervous system. *Glia*, *15*: 264–288, 1995.
24. Gillespie, G. Y. Cytokines as modulators of malignant glioma progression. *In*: R. R. Ransohoff, and E. N. Benveniste (eds.), *Cytokines and the CNS: Development, Defense, and Disease*, pp. 269–286. Boca Raton, FL: CRC Press, 1996.
25. Jaworski, D. M., Kelly, G. M., Piepmeier, J. M., and Hockfield, S. BEHAB (brain enriched hyaluronan binding) is expressed in surgical samples of glioma and in intracranial grafts of invasive glioma cell lines. *Cancer Res.*, *56*: 2293–2298, 1996.
26. Murphy, E. V., Zhang, Y., Zhu, W., and Biggs, J. The human glioma pathogenesis-related proteins structurally related to plant pathogenesis-related proteins and its gene expressed specifically in brain tumors. *Gene*, *159*: 131–135, 1995.
27. Ullrich, N., Gillespie, G. Y., and Sontheimer, H. Human astrocytoma cells express a unique chloride current. *NeuroReports*, *7*: 343–347, 1996.

# Clinical Cancer Research

## Receptor for Interleukin 13 Is a Marker and Therapeutic Target for Human High-Grade Gliomas

Waldemar Debinski, Denise M. Gibo, Stanley W. Hulet, et al.

*Clin Cancer Res* 1999;5:985-990.

**Updated version** Access the most recent version of this article at:  
<http://clincancerres.aacrjournals.org/content/5/5/985>

**Cited articles** This article cites 24 articles, 10 of which you can access for free at:  
<http://clincancerres.aacrjournals.org/content/5/5/985.full#ref-list-1>

**Citing articles** This article has been cited by 26 HighWire-hosted articles. Access the articles at:  
<http://clincancerres.aacrjournals.org/content/5/5/985.full#related-urls>

**E-mail alerts** [Sign up to receive free email-alerts](#) related to this article or journal.

**Reprints and Subscriptions** To order reprints of this article or to subscribe to the journal, contact the AACR Publications Department at [pubs@aacr.org](mailto:pubs@aacr.org).

**Permissions** To request permission to re-use all or part of this article, use this link  
<http://clincancerres.aacrjournals.org/content/5/5/985>.  
Click on "Request Permissions" which will take you to the Copyright Clearance Center's (CCC) Rightslink site.