

Minireview

Progression Model for Pancreatic Cancer¹

Ralph H. Hruban,² Michael Goggins,
Jennifer Parsons, and Scott E. Kern

Departments of Pathology [R. H. H., M. G., J. P., S. E. K.], Oncology [R. H. H., M. G., S. E. K.], and Gastroenterology [M. G.], The Johns Hopkins Medical Institutions, Baltimore, Maryland 21287

It has been >10 years since Vogelstein and colleagues (1, 2) proposed a progression model for colorectal neoplasia in which they hypothesized that the progression from normal colonic epithelium, to small adenomatous polyps, to infiltrating adenocarcinoma is associated with the activation of oncogenes and the inactivation of tumor suppressor genes. Mutations in the *APC* gene initiate the adenomatous process, resulting in the clonal growth of a single cell (3–5). Over the years, additional mutations can occur in these adenomas, resulting in waves of clonal expansion and competition among persistent subclones, increasing severity of dysplasia, and eventually in the development of an invasive adenocarcinoma (1, 2, 6, 7). This genetic progression model not only has formed the basis of our understanding of the mechanisms underlying the development of colorectal neoplasia, but it also has important implications for chemoprevention, for the development of genetic screening tests for the presymptomatic diagnosis of colorectal carcinomas, and for the development of prognostic genetic markers (8–10).

Pancreatic cancer is the fourth leading cause of cancer death in both men and women; yet, at the time the progression model was proposed for colorectal neoplasms, remarkably little was known about pancreatic cancer. For example, in 1988, the only significant genetic alteration that had been identified in pancreatic cancer was mutation of the *K-ras* oncogene (11). The last 10 years has seen, however, an explosion in our understanding of pancreatic cancer, and pancreatic cancer is now one of the better characterized neoplasms at the genetic level. We believe that there is now sufficient pathological, clinical, and genetic evidence for us to develop a rational progression model for pancreatic cancer.

The first clue that there may be a distinctive precursor lesion to infiltrating adenocarcinoma of the pancreas came from careful morphological studies (12). In 1976, Cubilla and Fitzgerald (13) reported a seminal paper in which they identified histologically distinct proliferative lesions in the pancreatic ducts and ductules adjacent to infiltrating adenocarcinomas of the pancreas. They called these duct lesions “hyperplasias” and

showed that they were more common in pancreata with cancer than they were in pancreata without cancer. Kozuka *et al.* (14) reported similar findings shortly thereafter, and more recently, Furukawa *et al.* (15), using three-dimensional mapping techniques, have demonstrated a stepwise progression from mild dysplasia to severe dysplasia in these pancreatic duct lesions (14–16). These observations were, however, static, and it was not universally agreed upon whether these pancreatic duct lesions represented the intraductal extension of an invasive cancer or a true precursor to invasive cancer (17).

Clinical studies were needed to establish the temporal relationship between pancreatic duct lesions and invasive carcinoma. These studies proved to be more difficult than one might hope because, unlike the colon, skin, breast, cervix, and prostate, the pancreas is not readily accessible to biopsy. Nonetheless, Brat *et al.* (18) have reported three patients who developed infiltrating ductal pancreatic adenocarcinoma 17 months to 10 years after the histological identification of atypical papillary duct lesions in their pancreata. Similarly, Brockie *et al.* (19) reported two patients with atypical papillary duct lesions who developed invasive pancreatic ductal carcinomas years later. Although there have only been a handful of such cases reported, they provide strong support that duct lesions in the pancreas can progress to invasive cancer (20).

Molecular genetic analyses have provided the third and most convincing line of evidence that pancreatic duct lesions are the precursors to infiltrating adenocarcinomas of the pancreas. Almost all of the genetic alterations that have been identified in infiltrating ductal adenocarcinomas of the pancreas have also been identified in these duct lesions, and remarkably, the prevalence of these genetic alterations increases as the degree of cytological and architectural atypia in the duct lesions increases (Fig. 1; Refs. 21–27).

Pancreatic duct lesions with minimal cytological and architectural atypia have been shown to harbor activating point mutations in the *K-ras* oncogene and to overexpress the *HER-2/neu* gene product (17, 21, 24, 28–31). For example, Day *et al.* (21) reported that *HER-2/neu* is only rarely overexpressed in histologically normal pancreatic ductal epithelium, but it is overexpressed in almost all duct lesions with significant cytological and architectural atypia. Similarly, ~45% of papillary pancreatic duct lesions without atypia harbor *K-ras* gene mutations, and the prevalence of these mutations in *K-ras* increases with increasing degrees of atypia in the duct lesions (reviewed in Ref. 22). These alterations in *K-ras* and *Her-2/neu* are believed to be “early” genetic events in the development of pancreatic neoplasia because they occur in pancreatic duct lesions with minimal atypia.

Inactivation of the *p16* tumor suppressor gene appears to occur slightly later. For example, the *p16* tumor suppressor gene is located on chromosome 9p, and Yamano *et al.* (32) have shown loss of heterozygosity at 9p in ~13% of histologically low-grade pancreatic duct lesions, whereas 90% of the histologically high-grade duct lesions that they examined had loss of heterozygosity of this chromosome arm. Similarly, Moskaluk *et*

Received 1/26/00; revised 4/24/00; accepted 5/8/00.

The costs of publication of this article were defrayed in part by the payment of page charges. This article must therefore be hereby marked *advertisement* in accordance with 18 U.S.C. Section 1734 solely to indicate this fact.

¹ Supported by NIH Grant P50-CA 62924.

² To whom requests for reprints should be addressed, at The Johns Hopkins Hospital, Meyer 7-181, 600 North Wolfe Street, Baltimore, MD 21287. Phone: (410) 955-9132; Fax: (410) 955-0115; E-mail: rhruban@jhmi.edu.

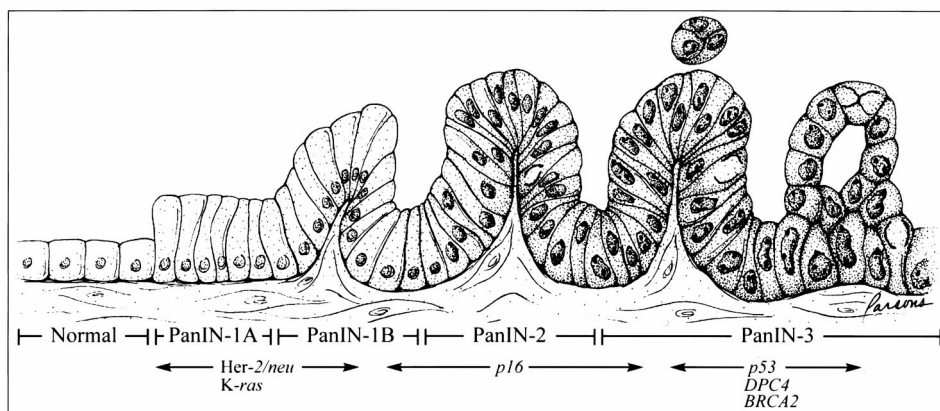


Fig. 1 Progression model for pancreatic cancer. Normal duct epithelium progresses to infiltrating cancer (left to right) through a series of histologically defined precursors (PanINs). The overexpression of HER-2/neu and point mutations in the K-ras gene occur early, inactivation of the p16 gene at an intermediate stage, and the inactivation of p53, DPC4, and BRCA2 occur relatively late.

al. (24) microdissected a series of duct lesions and demonstrated biallelic inactivation of the p16 gene in three of nine duct lesions. Wilentz *et al.* (23) extended these observations by immunohistochemically labeling over 125 pancreatic duct lesions for the p16 gene product. They not only confirmed that p16 is frequently inactivated, but they also correlated the loss of p16 gene expression with the severity cytological and architectural atypia in the duct lesions (23). Nine (30%) of 30 flat, 4 (27%) of 15 papillary, 37 (55%) of 67 papillary with atypia, and 10 (71%) of 14 carcinomas *in situ* duct lesions showed loss of p16 expression (23). The differences in p16 expression between the flat and papillary lesions and between the nonatypical and atypical duct lesions were statistically significant. Thus, loss of p16 expression occurs most frequently, but not exclusively, in higher-grade duct lesions.

Loss of the p53, DPC4, and BRCA2 tumor suppressor genes appears to occur late in the development of pancreatic neoplasia. Loss of heterozygosity at chromosome 17p (the location of the p53 gene) and at 18q (the location of the DPC4 gene), loss of DPC4 gene expression, abnormalities of p53 gene expression, and biallelic inactivation of the BRCA2 tumor suppressor gene have all also been reported in pancreatic duct lesions (22, 26, 27, 32, 33). However, in contrast to K-ras, HER-2/neu, and p16, these gene abnormalities appear to occur almost exclusively in duct lesions with significant cytological and architectural atypia (carcinoma *in situ*; reviewed in Refs. 22 and 34).

The timing of DNA methylation, of telomerase activation, and of a number of low frequency genetic alterations, such as inactivation of the MKK4, STK11, ALK5, and TGFBR2 tumor suppressor genes, remains to be defined (35–38).

These pathological, clinical, and molecular observations can now form the foundation for a progression model for pancreatic cancer. Just as there is a progression in the colorectum from normal colonic epithelium, to adenoma, to infiltrating carcinoma, so too is there a progression in the pancreas from normal ductal epithelium, to duct lesions, to invasive ductal adenocarcinoma (20). This progression is associated with multiple genetic alterations including activating point mutations in the K-ras gene, the overexpression of HER-2/neu, and the inactivation of the p16, p53, DPC4, and occasionally BRCA2

tumor suppressor genes. Although APC appears to be the “gate-keeper” gene in the development of colonic neoplasia, a gate-keeper gene for the initiation of pancreatic neoplasia has not been identified (3).

This model has a number of important implications:

(a) If we define a neoplasm as a clonal cell population that has highly patterned alterations in cancer-causing genes, then pancreatic duct lesions are true neoplasms. The nomenclature should reflect the neoplastic nature of these lesions, and indeed, the terminology PanIN³ was proposed by the National Cancer Institute-sponsored Pancreatic Think Tank held in Park City, Utah in September 1999.⁴

(b) This progression model suggests that molecular genetic based screening tests can be developed to detect early pancreatic neoplasms before they have spread beyond the gland (39, 40). For example, mutant K-ras genes can be detected in samples of duodenal fluid and stool from patients with pancreatic cancer, and Berthélemy *et al.* (41) have demonstrated that these genetic alterations may be present in samples of pancreatic secretions more than a year before a neoplasm is clinically apparent in the pancreas (28, 41–44).

(c) This progression model suggests that these early pancreatic duct lesions in the pancreas might also be reasonable targets for chemoprevention (45, 46). For example, the progression model for colorectal carcinoma has formed the basis for chemoprevention trials in patients with familial adenomatous polyposis (10). Similarly, patients with an inherited susceptibility to pancreatic cancer may also be a reasonable group to study the benefit of chemoprevention of pancreatic cancer (37, 47–52).

What doesn't this model suggest? This model doesn't imply that all PanINs progress to infiltrating carcinomas. Indeed, low-grade PanINs probably only rarely, if ever, progress, akin to aberrant crypt foci in the colon (53). Additional studies are needed to determine whether specific morphological findings or genetic abnormalities can predict which PanINs have a

³ The abbreviation used is: PanIN, pancreatic intraepithelial neoplasia.

⁴ Internet address: http://pathology.jhu.edu/pancreas_panin.

significant risk of progressing. The model also does not rule out other pathways for the development of infiltrating ductal adenocarcinomas. For example, it is possible that carcinomas with DNA replication errors progress through an alternate pathway (54). Additional studies are needed to examine such possibilities.

In summary, infiltrating carcinomas of the pancreas appear to arise from histologically well-defined precursor lesions in the small ducts and ductules of the pancreas. These lesions, called PanINs, harbor a number of well-characterized genetic alterations. A better understanding of the genetic progression in the pancreas will form the basis for future early detection and chemoprevention studies.

References

- Vogelstein, B., Fearon, E. R., Hamilton, S. R., Kern, S. E., Preisinger, A. C., Leppert, M., Nakamura, Y., White, R., Smits, A. M., and Bos, J. L. Genetic alterations during colorectal-tumor development. *N. Engl. J. Med.*, 319: 525–532, 1988.
- Vogelstein, B., and Kinzler, K. W. The multistep nature of cancer. *Trends Genet.*, 9: 138–141, 1993.
- Kinzler, K. W., and Vogelstein, B. Gatekeepers and caretakers. *Nature (Lond.)*, 386: 761–763, 1997.
- Fearon, E. R., Hamilton, S. R., and Vogelstein, B. Clonal analysis of human colorectal tumors. *Science (Washington DC)*, 238: 193–197, 1987.
- Powell, S. M., Zilz, N., Beazer-Barclay, Y., Bryan, T. M., Hamilton, S. R., Thibodeau, S. N., Vogelstein, B., and Kinzler, K. W. APC mutations occur early during colorectal tumorigenesis. *Nature (Lond.)*, 359: 235–237, 1992.
- Shibata, D., Schaeffer, J., Li, Z. H., Capella, G., and Perucho, M. Genetic heterogeneity of the c-K-ras locus in colorectal adenomas but not in adenocarcinomas [see comments]. *J. Natl. Cancer Inst.*, 85: 1058–1063, 1993.
- Bos, J. L., Fearon, E. R., Hamilton, S. R., Verlaan-de Vries, M., van Boom, J. H., van der Eb, A. J., and Vogelstein, B. Prevalence of *ras* gene mutations in human colorectal cancers. *Nature (Lond.)*, 327: 293–297, 1987.
- Kern, S. E., Fearon, E. R., Tersmette, K. W. F., Enterline, J. P., Leppert, M., Nakamura, Y., White, R., Vogelstein, B., and Hamilton, S. R. Clinical and pathological associations with allelic loss in colorectal carcinoma. *J. Am. Med. Assoc.*, 261: 3099–3103, 1989.
- Sidransky, D., Tokino, T., Hamilton, S. R., Kinzler, K. W., Levin, B., Frost, P., and Vogelstein, B. Identification of *ras* oncogene mutations in the stool of patients with curable colorectal tumors. *Science (Washington DC)*, 256: 102–105, 1992.
- Giardiello, F. M., Hamilton, S. R., Krush, A. J., Piantadosi, S., Hyland, L. M., Celano, P., Booker, S. V., Robinson, C. R., and Offerhaus, G. J. Treatment of colonic and rectal adenomas with sulindac in familial adenomatous polyposis. *N. Engl. J. Med.*, 328: 1313–1316, 1993.
- Almoguera, C., Shibata, D., Forrester, K., Martin, J., Arnheim, N., and Perucho, M. Most human carcinomas of the exocrine pancreas contain mutant c-K-ras genes. *Cell*, 53: 549–554, 1988.
- Sommers, S. C., Murphy, S. A., and Warren, S. Pancreatic duct hyperplasia and cancer. *Arch. Pathol.*, 27: 629–640, 1954.
- Cubilla, A. L., and Fitzgerald, P. J. Morphological lesions associated with human primary invasive nonendocrine pancreas cancer. *Cancer Res.*, 36: 2690–2698, 1976.
- Kozuka, S., Sassa, R., Taki, T., Masamoto, K., Nagasawa, S., Saga, S., Hasegawa, K., and Takeuchi, M. Relation of pancreatic duct hyperplasia to carcinoma. *Cancer (Phila.)*, 43: 1418–1428, 1979.
- Furukawa, T., Chiba, R., Kobari, M., Matsuno, S., Nagura, H., and Takahashi, T. Varying grades of epithelial atypia in the pancreatic ducts of humans. Classification based on morphometry and multivariate analysis and correlated with positive reactions of carcinoembryonic antigen. *Arch. Pathol. Lab. Med.*, 118: 227–234, 1994.
- Klöpffel, G., Bommer, G., Rückert, K., and Seifert, G. Intraductal proliferation in the pancreas and its relationship to human and experimental carcinogenesis. *Virchows Arch. A Pathol. Anat. Hist.*, 387: 221–233, 1980.
- Lüttges, J., Schlehe, B., Menke, M. A., Vogel, I., Henne-Bruns, D., and Klöpffel, G. The K-ras mutation pattern in pancreatic ductal adenocarcinoma usually is identical to that in associated normal, hyperplastic, and metaplastic ductal epithelium. *Cancer (Phila.)*, 85: 1703–1710, 1999.
- Brat, D. J., Lillemoe, K. D., Yeo, C. J., Warfield, P. B., and Hruban, R. H. Progression of pancreatic intraductal neoplasias (high-grade PanIN) to infiltrating adenocarcinoma of the pancreas. *Am. J. Surg. Pathol.*, 22: 163–169, 1998.
- Brockie, E., Anand, A., and Albores-Saavedra, J. Progression of atypical ductal hyperplasia/carcinoma *in situ* of the pancreas to invasive adenocarcinoma. *Ann. Diagn. Pathol.*, 2: 286–292, 1998.
- Hruban, R. H., Wilentz, R. E., Goggins, M., Offerhaus, G. J. A., Yeo, C. J., and Kern, S. E. Pathology of incipient pancreatic cancer. *Ann. Oncol.*, 10: S9–S11, 1999.
- Day, J. D., DiGiuseppe, J. A., Yeo, C. J., Loi-Goldman, M., Anderson, S., Kern, S. E., and Hruban, R. H. Immunohistochemical evaluation of HER-2/*neu* oncogene expression in pancreatic adenocarcinoma and pancreatic intraepithelial neoplasms. *Hum. Pathol.*, 27: 119–124, 1996.
- Wilentz, R. E., Iacobuzio-Donahue, C. A., Argani, P., McCarthy, D. M., Parsons, J. L., Yeo, C. J., Kern, S. E., and Hruban, R. H. Loss of expression of Dpc4 in pancreatic intraepithelial neoplasia: evidence that *DPC4* inactivation occurs late in neoplastic progression. *Cancer Res.*, 60: 2002–2006, 2000.
- Wilentz, R. E., Geradts, J., Maynard, R., Offerhaus, G. J. A., Kang, M., Goggins, M., Yeo, C. J., Kern, S. E., and Hruban, R. H. Inactivation of the *p16 (INK4A)* tumor-suppressor gene in pancreatic duct lesions: loss of intranuclear expression. *Cancer Res.*, 58: 4740–4744, 1998.
- Moskaluk, C. A., Hruban, R. H., and Kern, S. E. *p16* and *K-ras* gene mutations in the intraductal precursors of human pancreatic adenocarcinoma. *Cancer Res.*, 57: 2140–2143, 1997.
- DiGiuseppe, J. A., Hruban, R. H., Offerhaus, G. J. A., Clement, M. J., van den Berg, F. M., Cameron, J. L., and van Mansfeld, A. D. M. Detection of *K-ras* mutations in mucinous pancreatic duct hyperplasia from a patient with a family history of pancreatic carcinoma. *Am. J. Pathol.*, 144: 889–895, 1994.
- DiGiuseppe, J. A., Hruban, R. H., Goodman, S. N., Polak, M., van den Berg, F. M., Allison, D. C., Cameron, J. L., and Offerhaus, G. J. A. Overexpression of p53 protein in adenocarcinoma of the pancreas. *Am. J. Clin. Pathol.*, 101: 684–688, 1994.
- Goggins, M., Hruban, R. H., and Kern, S. E. BRCA2 is inactivated late in the development of pancreatic intraepithelial neoplasia: evidence and implications. *Am. J. Pathol.*, 156: 1767–1771, 2000.
- Caldas, C., Hahn, S. A., Hruban, R. H., Redston, M. S., Yeo, C. J., and Kern, S. E. Detection of *K-ras* mutations in the stool of patients with pancreatic adenocarcinoma and pancreatic ductal hyperplasia. *Cancer Res.*, 54: 3568–3573, 1994.
- Tada, M., Ohashi, M., Shiratori, Y., Okudaira, T., Komatsu, Y., Kawabe, T., Yoshida, H., Machinami, R., Kishi, K., and Omata, M. Analysis of *K-ras* gene mutation in hyperplastic duct cells of the pancreas without pancreatic disease. *Gastroenterology*, 110: 227–231, 1996.
- Yanagisawa, A., Ohtake, K., Ohashi, K., Hori, M., Kitagawa, T., Sugano, H., and Kato, Y. Frequent c-Ki-ras oncogene activation in mucous cell hyperplasias of pancreas suffering from chronic inflammation. *Cancer Res.*, 53: 953–956, 1993.
- Terhune, P. G., Phifer, D. M., Tosteson, T. D., and Longnecker, D. S. *K-ras* mutation in focal proliferative lesions of human pancreas. *Cancer Epidemiol. Biomark. Prev.*, 7: 515–521, 1998.
- Yamano, M., Fujii, H., Takagaki, T., Kadowaki, N., Watanabe, H., and Shirai, T. Genetic progression and divergence in pancreatic carcinoma. *Am. J. Pathol.*, 156: 2123–2133, 2000.
- Hameed, M., Marrero, A. M., Conlon, K. C., Brennan, M. F., and Klimstra, D. S. Expression of p53 nucleophosphoprotein in *in situ*

- pancreatic ductal adenocarcinoma: an immunohistochemical analysis of 100 cases. *Lab. Invest.*, 70: 132A, 1994.
34. Hruban, R. H., Wilentz, R. E., and Kern, S. E. Genetic progression in the pancreatic ducts. *Am. J. Pathol.*, 156: 1821–1825, 2000.
35. Su, G. H., Hilgers, W., Shekher, M., Tang, D., Yeo, C. J., Hruban, R. H., and Kern, S. E. Alterations in pancreatic, biliary, and breast carcinomas support *MKK4* as a genetically targeted tumor-suppressor gene. *Cancer Res.*, 58: 2339–2342, 1998.
36. Ueki, T., Toyota, M., Sohn, T. A., Yeo, C. J., Issa, J.-P. J., Hruban, R. H., and Goggins, M. Hypermethylation of multiple genes in pancreatic carcinoma. *Cancer Res.*, 60: 1835–1839, 2000.
37. Su, G. H., Hruban, R. H., Bova, G. S., Goggins, M., Bansal, R. K., Tang, D. T., Shekher, M. C., Westerman, A.-M., Entius, M. M., Yeo, C. J., and Kern, S. E. Germline and somatic mutations of the *STK11/LKB1* Peutz-Jeghers gene in pancreatic and biliary cancers. *Am. J. Pathol.*, 154: 1835–1840, 1999.
38. Goggins, M., Shekher, M., Kenan, T., Yeo, C. J., Hruban, R. H., and Kern, S. E. Genetic alterations of the transforming growth factor β receptor genes in pancreatic and biliary adenocarcinomas. *Cancer Res.*, 58: 5329–5332, 1998.
39. Wilentz, R. E., and Hruban, R. H. Pathology of cancer of the pancreas. *Surg. Oncol. Clin. N. Am.*, 7: 43–65, 1998.
40. Wilentz, R. E., Slebos, R. J. C., and Hruban, R. H. Screening for pancreatic cancer using techniques to detect altered gene products. In: H. A. Reber (ed.), *Pancreatic Cancer: Pathogenesis, Diagnosis, and Treatment*, pp. 113–136. Totowa, NJ: Humana Press, Inc., 1997.
41. Berthélemy, P., Bouisson, M., Escourrou, J., Vaysse, N., Rumeau, J. L., and Pradayrol, L. Identification of K-ras mutations in pancreatic juice in the early diagnosis of pancreatic cancer. *Ann. Intern. Med.*, 123: 188–191, 1995.
42. Tada, M., Omata, M., Kawai, S., Saisho, H., Ohto, M., Saiki, R. K., and Sninsky, J. J. Detection of *ras* gene mutations in pancreatic juice and peripheral blood of patients with pancreatic adenocarcinoma. *Cancer Res.*, 53: 2472–2474, 1993.
43. Brentnall, T. A., Bronner, M. P., Byrd, D. R., Haggitt, R. C., and Kimmey, M. B. Early diagnosis and treatment of pancreatic dysplasia in patients with a family history of pancreatic cancer. *Ann. Intern. Med.*, 131: 247–255, 1999.
44. Wilentz, R. E., Chung, C. H., Sturm, P. D. J., Musler, A., Sohn, T. A., Offerhaus, G. J. A., Yeo, C. J., Hruban, R. H., and Slebos, R. J. C. K-ras mutations in the duodenal fluid of patients with pancreatic carcinoma. *Cancer (Phila.)*, 82: 96–103, 1998.
45. Hong, W. K., and Sporn, M. B. Recent advances in chemoprevention of cancer. *Science (Washington DC)*, 278: 1073–1077, 1997.
46. Tucker, O. N., Dannenberg, A. J., Yang, E. K., Zhang, F., Teng, L., Daly, J. M., Soslow, R. A., Masferrer, J. L., Woerner, B. M., Koki, A. T., and Fahey, T. J. Cyclooxygenase-2 expression is up-regulated in human pancreatic cancer. *Cancer Res.*, 59: 987–990, 1999.
47. Goggins, M., Schutte, M., Lu, J., Moskaluk, C. A., Weinstein, C. L., Petersen, G. M., Yeo, C. J., Jackson, C. E., Lynch, H. T., Hruban, R. H., and Kern, S. E. Germline *BRCA2* gene mutations in patients with apparently sporadic pancreatic carcinomas. *Cancer Res.*, 56: 5360–5364, 1996.
48. Goldstein, A. M., Fraser, M. C., Struewing, J. P., Hussussian, C. J., Ranade, K., Zametkin, D. P., Fontaine, L. S., Organic, S. M., Dracopoli, N. C., Clark, W. H., and Tucker, M. A. Increased risk of pancreatic cancer in melanoma-prone kindreds with p16 INK4 mutations. *N. Engl. J. Med.*, 333: 970–974, 1995.
49. Moskaluk, C. A., Hruban, R. H., Lietman, A., Smyrk, T., Fusaro, L., Fusaro, R., Lynch, J., Yeo, C. J., Jackson, C., and Kern, S. E. Novel germline *p16^{INK4}* allele (Asp145Cys) in a family with multiple pancreatic carcinomas. *Hum. Mutat.*, 12: 70, 1998.
50. Lowenfels, A. B., Maisonneuve, E. P., Dimagno, Y. E., Gates, L. K., Perrault, J., Whitcomb, D. C., and International Hereditary Pancreatitis Study Group. Hereditary pancreatitis and the risk of pancreatic cancer. *J. Natl. Cancer Inst.*, 89: 442–446, 1997.
51. Hruban, R. H., Petersen, G. M., Goggins, M., Tersmette, A. C., Offerhaus, G. J. A., Falatko, F., and Kern, S. E. Familial pancreatic cancer. *Ann. Oncol.*, 10: S69–S73, 1999.
52. Hruban, R. H., Petersen, G. M., Ha, P. K., and Kern, S. E. Genetics of pancreatic cancer: From genes to families. *Surg. Oncol. Clin. N. Am.*, 7: 1–23, 1998.
53. Nascimbeni, R., Villanacci, V., Mariani, P. P., Di Betta, E., Ghirardi, M., Donato, F., and Salerni, B. Aberrant crypt foci in the human colon: frequency and histologic patterns in patients with colorectal cancer or diverticular disease. *Am. J. Surg. Pathol.*, 23: 1256–1263, 1999.
54. Goggins, M., Offerhaus, G. J. A., Hilgers, W., Griffin, C. A., Shekher, M., Tang, D., Sohn, T. A., Yeo, C. J., Kern, S. E., and Hruban, R. H. Pancreatic adenocarcinomas with DNA replication errors (RER+) are associated with wild-type K-ras and characteristic histopathology: poor differentiation, a syncytial growth pattern, and pushing borders suggest RER+. *Am. J. Pathol.*, 152: 1501–1507, 1998.

Clinical Cancer Research

Progression Model for Pancreatic Cancer

Ralph H. Hruban, Michael Goggins, Jennifer Parsons, et al.

Clin Cancer Res 2000;6:2969-2972.

Updated version Access the most recent version of this article at:
<http://clincancerres.aacrjournals.org/content/6/8/2969>

Cited articles This article cites 50 articles, 16 of which you can access for free at:
<http://clincancerres.aacrjournals.org/content/6/8/2969.full#ref-list-1>

Citing articles This article has been cited by 100 HighWire-hosted articles. Access the articles at:
<http://clincancerres.aacrjournals.org/content/6/8/2969.full#related-urls>

E-mail alerts [Sign up to receive free email-alerts](#) related to this article or journal.

Reprints and Subscriptions To order reprints of this article or to subscribe to the journal, contact the AACR Publications Department at pubs@aacr.org.

Permissions To request permission to re-use all or part of this article, use this link
<http://clincancerres.aacrjournals.org/content/6/8/2969>.
Click on "Request Permissions" which will take you to the Copyright Clearance Center's (CCC) Rightslink site.