

Expression of the *Endostatin* Gene in Epithelial Ovarian Cancer

Kohkichi Hata,¹ Ritsuto Fujiwaki,
Kentaro Nakayama, and Kohji Miyazaki

Department of Obstetrics and Gynecology, Shimane Medical University, Izumo 693-8501, Japan

ABSTRACT

Endostatin, a M_r 20,000 COOH-terminal fragment of collagen XVIII, is currently in preclinical development as a novel antiangiogenic agent. The gene expression of this molecule in 23 normal ovaries with follicle or corpus luteum and in 64 cases of epithelial ovarian cancer (27 serous, 18 mucinous, 13 endometrioid, 4 clear cell, and 2 undifferentiated carcinomas) was analyzed by PCR of RNA after reverse transcription. Seven of the cases were of low malignant potential. With regard to staging, 23 cases had stage I disease, 5 had stage II disease, 29 had stage III disease, and 7 had stage IV disease. The level of *endostatin* gene expression was described in terms of the ratio of the relative yield of the *endostatin* gene to that of the β 2-microglobulin gene. *Endostatin* gene expression in ovarian cancers (median, 0.14; range, 0.02–1.11) was significantly higher than that in normal ovaries with follicle or corpus luteum (median, 0.08; range, 0.03–0.26; $P = 0.009$). International Federation of Gynecology and Obstetrics stage ($P = 0.009$) and residual tumor ($P = 0.005$) were significantly associated with *endostatin* gene expression; however, other clinicopathological features (*e.g.*, patient age at diagnosis, histological subtype, and histological grade) were not significantly associated with *endostatin* gene expression. Survival data were available for all patients. Univariate Cox regression analysis showed the prognosis of the patients with high *endostatin* gene expression [equal to or greater than the median (≥ 0.14)] to be significantly worse than that of patients with low *endostatin* gene expression [less than the median (< 0.14); $P = 0.044$]. Our results with regard to the gene expression of this endogenous inhibitor of angiogenesis present a new insight to understand the biology of epithelial ovarian cancer and may lead to the development of a new therapeutic strategy for epithelial ovarian cancer.

INTRODUCTION

For many years, the combination of cyclophosphamide-cisplatin was used as the standard of care for the treatment of ovarian cancer; then, however, a large randomized study proved

that a combination of paclitaxel and cisplatin resulted in a better response rate and an improvement in progression-free interval and survival (1). Recently, Neijt *et al.* (2) reported that paclitaxel-carboplatin is a feasible regimen for outpatients with ovarian cancer and has a better toxicity profile than paclitaxel-cisplatin. However, they could not draw any conclusions about the efficacy of the two regimens in comparison with each other. The overall 5-year survival rate for patients with FIGO² stage IIb to IV disease treated by this new chemotherapeutic regimen was about 30% (2). The early stages of malignant growth in the ovary do not usually produce symptoms, and late diagnosis is probably the main reason for the poor prognosis. An improved understanding of the mechanisms regulating the growth of ovarian cancer cells may eventually lead to techniques that facilitate early diagnosis, establishment of prognosis, or determination of response to therapy.

The growth and progression of tumors is dependent on the process of angiogenesis. This process begins when a pinpoint colony of tumor cells expands to a size where simple diffusion of nutrients (and wastes) is insufficient. New capillaries are elicited, and the tumor then enters a phase in which perfusion becomes the mechanism by which nutrients arrive and metabolic wastes are carried away (3). Therefore, blood supply is a critical factor for the growth and progression of the tumor. Recently, we have reported that gene expression of TP [an angiogenic factor (4, 5)] and AM [a vasodilatory peptide (6)] assessed by RT-PCR was significantly associated with poor prognosis in patients with epithelial ovarian cancer. The development of antivascular therapy is anticipated in epithelial ovarian cancer.

Endostatin, a M_r 20,000 COOH-terminal fragment of collagen XVIII, is currently in preclinical development as a novel antiangiogenic agent (7). Mouse endostatin was initially isolated from the conditioned media of a murine hemangi endothelioma cell line (8). Mouse endostatin, a potent inhibitor of angiogenesis *in vitro* and *in vivo*, has demonstrated potent antitumor activity *in vivo* without the development of resistance (8, 9). Human serum and tissue forms of endostatin have also been identified (10, 11), and the inhibitory effect of endostatin on angiogenesis has been reported previously (12). In the present study, we have examined mRNA expression of endostatin using RT-PCR in 23 ovaries with follicle or CL and 64 cases of epithelial ovarian cancer. The gene expression of this endogenous inhibitor of angiogenesis has been related to clinical and pathological parameters to further evaluate the role of endostatin in epithelial ovarian cancer.

Received 3/5/01; revised 5/15/01; accepted 5/16/01.

The costs of publication of this article were defrayed in part by the payment of page charges. This article must therefore be hereby marked *advertisement* in accordance with 18 U.S.C. Section 1734 solely to indicate this fact.

¹ To whom requests for reprints should be addressed. Phone: 81-853-20-2268; Fax: 81-853-20-2264; E-mail: hata31@shimane-med.ac.jp.

² The abbreviations used are: FIGO, International Federation of Gynecology and Obstetrics; CL, corpus luteum; RT-PCR, reverse transcription-PCR; β 2-MG, β 2-microglobulin; TP, thymidine phosphorylase; AM, adrenomedullin; LMP, low malignant potential.

MATERIALS AND METHODS

Patients. The 23 patients that had normal ovaries with follicle or CL ranged in age from 21–50 years (median age, 43 years), and all subjects had regular menstrual cycles. The final diagnoses were myoma uteri and/or adenomyosis ($n = 14$), cervical cancer stage Ib ($n = 2$), serous cystadenoma ($n = 4$), mucinous cystadenoma ($n = 2$), and hemorrhagic CL ($n = 1$).

Patients were selected from among those with epithelial ovarian cancer treated between October 1989 and December 1999 at the Shimane Medical University Hospital (Izumo, Japan). Eligible patients had a histological diagnosis of primary epithelial ovarian cancer and were suitable for adequate surgical staging. Patients were excluded from this study if fresh, surgically resected specimens could not be obtained or were excluded preoperatively if they had undergone any therapy, had multiple cancers, or had severe complications. All research was conducted with patients' informed consent and with the approval of the hospital research ethics board. The median age of the 64 eligible patients was 54 years (range, 19–87 years). Twenty-six of them were premenopausal. The patients were staged according to the 1987 criteria recommended by FIGO (13). There were 23 stage I patients, 5 stage II patients, 29 stage III patients, and 7 stage IV patients. The staging system defined by FIGO, as described elsewhere (4, 6), assumes that an adequate staging operation has been performed. Tumors were classified histologically according to the WHO criteria (14) as serous ($n = 27$), mucinous ($n = 18$), endometrioid ($n = 13$), clear cell ($n = 4$), and undifferentiated ($n = 2$). The tumors were classified histologically as either having LMP ($n = 7$) or being well differentiated ($n = 13$), moderately differentiated ($n = 24$), or poorly differentiated [$n = 20$ (15)].

The surveillance for recurrent disease usually consisted of physical examination, Papanicolaou smear, and serology with tumor marker examination (e.g., CA 125, CA 19-9, carcinoembryonic antigen, sialyl Tn) every month for the first year, every 2 months for the second and third year, and every 3 months for the fourth and fifth year. After 5 years, the patients were examined semiannually. A chest radiograph and computed tomography scan or ultrasonography were obtained every 6 months for 5 years after surgery and every year thereafter; if necessary, magnetic resonance imaging was performed. Recurrent disease was proven pathologically, radiographically, or serologically. Follow-up information was obtained from medical records, letter or telephone contact with patients, and information from the referring physician. Survival data were available for all patients (median, 24 months; range, 2–120 months). Of these, 59 patients received cisplatin-containing regimens. Four stage I tumors of LMP and one stage I tumor of mucinous cystadenocarcinoma received no further treatment after surgery.

Fourteen of the patients with normal ovaries and 47 of the ovarian cancer patients had participated in previous studies (5, 6).

Tissue Specimen and RNA Preparation. Fresh surgical specimens were obtained from all patients, and the tissues to be used for investigation were prepared carefully under a dissecting microscope to dissect ovaries into hypervascular areas around the follicle and CL and cancerous tissue. Inappropriate components were eliminated. The tissue samples were stored at -80°C

for subsequent analysis. This method has been described in the previous investigation (4–6).

RT-PCR. RT-PCR for determination of *endostatin* gene expression was performed according to the method described previously (4–6). Total RNA was isolated from frozen tissue using a commercially available extraction method (Isogen; Nippon Gene Inc., Tokyo, Japan). Briefly, cDNA was prepared by random priming from 500 ng of total RNA using a First-Strand cDNA Synthesis kit (Pharmacia-LKB, Uppsala, Sweden). Primers for *endostatin* gene (GenBank accession number AF018081) amplification were ATGCTGACATTCACCTGCC (upstream) and ATGAAGTCAGCACCTGCTGG (downstream), and the PCR product was 172 bp. The primers were set based on the coding sequence of endostatin in human collagen XVIII (16). Moreover, primers for the non-endostatin-coding sequence (*non-endostatin* gene) were chosen (GenBank accession number AF018081; upstream primer, GCAGCCACAGCAGAT-ACCA; downstream primer, CACCGGAATGTTCTCTCT; PCR product, 167-bp fragment). PCR was carried out in a Thermal Cycler (Perkin-Elmer Cetus, Northwalk, CT) with a mixture consisting of cDNA derived from 5 ng of RNA, 10 pmol of upstream and downstream primers for the sequences of the *endostatin* gene, 5 pmol of primers for the β_2 -MG gene (GenBank accession number V00567; upstream primer, ACCCCACTGAAAAAGATGAG; downstream primer, ATCT-TCAAACCTCCATGATGC; PCR product, a 120-bp fragment), 200 μmol of deoxynucleotide triphosphate, and 0.1 unit of Taq DNA polymerase with reaction buffer (Life Technologies, Inc., Rockville, MD) in a final volume of 10 μl . The conditions for PCR were denaturation at 94°C for 1 min, annealing at 58°C for 1 min, and extension at 72°C for 1 min. Thirty-four cycles of PCR were performed for each specimen, and the products were separated on 9% polyacrylamide gels. The bands were then visualized by ethidium bromide staining. NIH analysis software version 1.61 (NIH, Bethesda, MD) was used to scan the RT-PCR polyacrylamide gels after photographic documentation. The software measures relative mean density over a fixed gray scale range after correction for background. The endostatin expression was described in terms of the relative yield of the *endostatin* gene to that of the β_2 -MG gene.

Statistical Analysis. Mann-Whitney U test and Kruskal-Wallis one-way ANOVA by ranks were used as appropriate for evaluation of differences between end points. The Cox proportional hazards model was used in survival analysis. Maximum likelihood parameter estimates and likelihood ratio statistics in the Cox proportional hazards models were obtained with the use of a statistical package, EPICURE (17). Kaplan-Meier curves were compared by the univariate Cox regression analysis. All P s presented were two-sided. $P < 0.05$ was considered significant.

RESULTS

RT-PCR and Endostatin and Non-endostatin Gene Expression. To determine the number of PCR cycles appropriate for quantification, PCR was performed from 22–40 cycles at an increment of 2 cycles. The expression ratios of endostatin and non-endostatin to β_2 -MG were reasonably constant from 24–34 cycles, respectively (data not shown). Therefore, in the subsequent experiments, the values at 30 PCR cycles

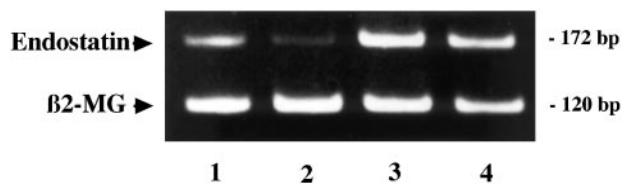


Fig. 1 Representative *endostatin* gene expression by RT-PCR (Lanes 1 and 2; normal ovary; Lanes 3 and 4; ovarian cancer).

were defined as the expression of target genes. The representative profile of *endostatin* gene expression by RT-PCR is shown in Fig. 1. Furthermore, the sequences of PCR products were analyzed, and they were identical to the sequence of the *endostatin* and *non-endostatin* gene, respectively. There was no significant correlation between the expression of the *endostatin* and *non-endostatin* gene in normal ovary ($P = 0.208$) and ovarian cancer ($P = 0.082$), respectively. Therefore, the *endostatin* gene expression obtained from RT-PCR in this investigation seemed to be independent of *collagen XVIII* gene activity.

Endostatin Gene Expression and Clinicopathological Features. *Endostatin* gene expression of ovarian cancers (median, 0.14; range, 0.02–1.11) was significantly higher than that of normal ovaries with follicle or CL (median, 0.08; range, 0.03–0.26; $P = 0.009$). No significant difference was noted between ovaries with follicle versus CL in terms of *endostatin* gene expression ($P = 0.564$). The gene expression values are mean values from at least three independent RT-PCR experiments. The values of *endostatin* gene expression in ovarian cancers are classified according to patient age at diagnosis, stage of disease, residual tumor mass after initial surgery, histological subtype, and grade (Table 1). FIGO stage ($P = 0.009$) and residual tumor ($P = 0.005$) were significantly associated with *endostatin* gene expression.

Endostatin Gene Expression and Prognosis. In a follow-up study of 42 cases after complete resection of the primary tumors by surgical operation, *endostatin* gene expression of the 9 patients who experienced recurrence (median, 0.10; range, 0.02–0.59) was statistically the same as that of 33 patients without recurrence (median, 0.24; range, 0.04–1.44). As shown in Fig. 2, we found the prognosis of the patients with high *endostatin* gene expression [equal to or greater than the median (≥ 0.14)] to be significantly worse than that of patients with low *endostatin* gene expression [less than the median (< 0.14)] by univariate Cox regression analysis ($P = 0.044$). Moreover, FIGO stage (III–IV; $P = 0.0006$) and residual disease (> 2 cm; $P = 0.001$) were found to be significantly associated with a poor prognosis in univariate Cox regression analysis (Table 2). Serous tumors and poorly differentiated tumors are generally thought to be more aggressive than other histological subtypes and other grades, respectively (18). However, such findings were not noted in this study (Table 2). Multivariate Cox regression analysis revealed that FIGO stage III–IV is an independent prognostic factor ($P = 0.038$; Table 3).

DISCUSSION

Collagen XVIII is an extracellular matrix protein identified by cDNA cloning (19, 20). The function and significance of this

Table 1 Clinicopathological features and *endostatin* gene expression

Clinicopathological features	<i>Endostatin</i> gene expression	
	Median (range)	<i>P</i>
Age at the time of diagnosis		0.984
≤ 50 yrs ($n = 26$)	0.13 (0.02–0.83)	
> 50 yrs ($n = 38$)	0.14 (0.03–1.11)	
FIGO stage		0.009
I–II ($n = 28$)	0.10 (0.02–0.60)	
III–IV ($n = 36$)	0.17 (0.04–1.11)	
Residual disease		0.005
≤ 2 cm ($n = 42$)	0.10 (0.02–1.04)	
> 2 cm ($n = 22$)	0.22 (0.04–1.11)	
Histological subtype		0.879
Serous ($n = 27$)	0.16 (0.03–1.04)	
Mucinous ($n = 18$)	0.10 (0.02–1.11)	
Endometrioid ($n = 13$)	0.14 (0.04–0.83)	
Clear cell ($n = 4$)	0.06 (0.03–0.60)	
Histological grade		0.335
LMP ($n = 7$)	0.10 (0.03–0.22)	
Well differentiated ($n = 13$)	0.16 (0.05–0.60)	
Moderately differentiated ($n = 24$)	0.14 (0.04–0.83)	
Poorly differentiated ($n = 20$)	0.16 (0.02–1.11)	

molecule is not known, but a M_r 20,000 proteolytic fragment called endostatin that is released from the COOH terminus of the collagen XVIII chain has been shown to inhibit endothelial cell proliferation, angiogenesis, and tumor growth (8). The regulation of angiogenesis is thought to be controlled by a balance of stimulators and inhibitors (21). Many of the angiogenesis inhibitors identified to date are fragments of large molecules. Recently, Wen *et al.* (22) suggested that the generation of endostatin from collagen XVIII is at least a two-step process, involving a metal-dependent early step and an elastase activity-dependent final step based on the cell culture study of heman-gioendothelioma. In this study, *endostatin* gene expression of ovarian cancers was significantly higher than that of normal ovaries with follicle or CL. This might reflect a biological difference between physiological and pathological angiogenesis in the generation activity of endostatin from collagen XVIII. The range of *endostatin* gene expression of ovarian cancers was larger than that of normal ovaries. The generation activity of endostatin from collagen XVIII might also differ according to the state of pathological angiogenesis each epithelial ovarian cancer bears.

Many locally advanced human cancers are resected for apparent cure after the usual systemic work-up for metastases proves negative. However, explosive metastatic recurrence after such resection for advanced disease is not an uncommon clinical observation (23). This clinical observation has been recreated in animal tumor models, in which the growth of small lesions is suppressed in the presence of a large primary tumor and is termed concomitant tumor resistance (24, 25). O'Reilly *et al.* (26) have proposed that a primary tumor, which is capable of stimulating angiogenesis in its own vascular bed, simultaneously inhibits angiogenesis in vascular beds of secondary, metastatic lesions. Circulating factors produced by the primary tumor are responsible for the suppression of distant tumor growth. One of these factors is endostatin, which was identified from the urine of mice bearing Lewis lung carcinoma (8).

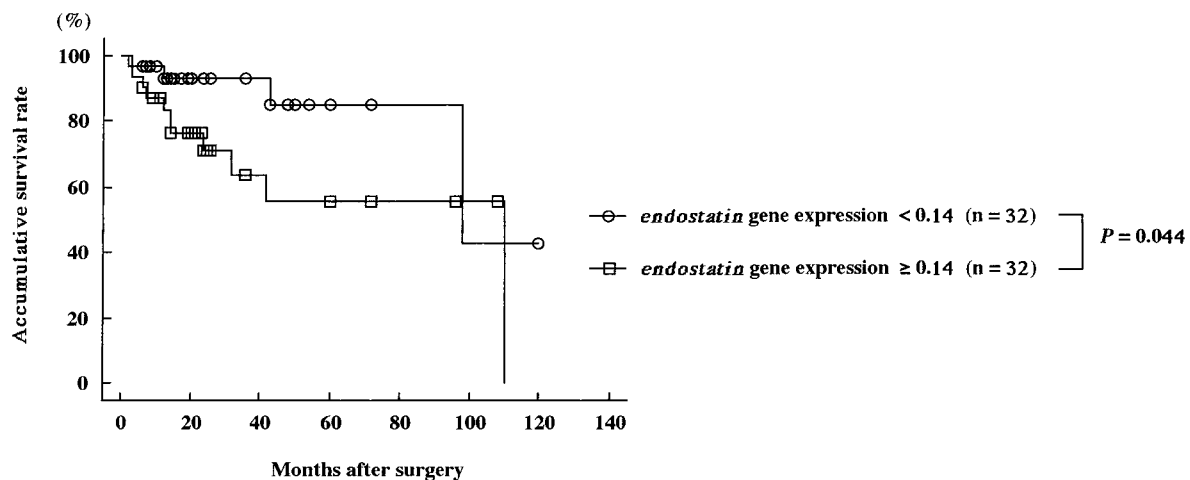


Fig. 2 Comparison of survival between groups with high *endostatin* gene expression [equal to or greater than the median (≥ 0.14)] and groups with low *endostatin* gene expression [less than the median (< 0.14)] according to univariate Cox regression analysis.

Table 2 The results of univariate Cox regression analysis

Valuables	Hazard ratio	95% confidence interval	P
Age at the time of diagnosis			
≤50 yrs (n = 26)	Referent		
>50 yrs (n = 38)	1.70	0.55–6.28	0.366
FIGO stage			
I–II (n = 28)	Referent		
III–IV (n = 36)	12.53	2.51–227.34	0.0006
Residual disease			
≤2 cm (n = 42)	Referent		
>2 cm (n = 22)	6.45	2.06–24.14	0.001
Histological subtype			
Serous (n = 27)	Referent		
Others (n = 37)	1.30	0.46–3.94	0.621
Histological grade			
Others (n = 44)	Referent		
Poorly differentiated (n = 20)	2.56	0.87–7.54	0.086
<i>Endostatin</i> gene expression			
<0.14 (n = 32)	Referent		
≥0.14 (n = 32)	3.03	1.03–10.95	0.044

Table 3 The results of multivariate Cox regression analysis

Valuables	Hazard ratio	95% confidence interval	P
FIGO stage			
I–II (n = 26)	Referent		
III–IV (n = 38)	6.81	1.10–132.53	0.038
Residual disease			
≤2 cm (n = 42)	Referent		
>2 cm (n = 22)	2.99	0.89–12.16	0.076
<i>Endostatin</i> gene expression			
<0.14 (n = 32)	Referent		
≥0.14 (n = 32)	1.28	0.41–4.90	0.683

We noted that FIGO stage and residual tumor were significantly associated with *endostatin* gene expression. This finding indicates that there might be a possible release of an inhibitory effect that the primary tumor has over disseminated tumor cells in epithelial ovarian cancer. Moreover, elevated *endostatin* gene expression is significantly correlated with reduced survival when examined by univariate analysis. The principle of our treatment was primary cytoreductive surgery before chemotherapy. The ovarian cancer might tend to undergo compensatory growth after tumor resection due to the loss of inhibitor factor, i.e., endostatin. Consequently, therapy that reduces the tumor mass may tend to accelerate the growth of the remaining tumor and tumor metastases. However, this speculation is putative because multivariate analysis demonstrated that *endostatin* gene expression is not an independent prognostic factor among the clinicopathological parameters studied. Moreover, it has to be noted that the number of cases was limited.

TP and *AM* gene expression was measured in 34 and 47 of 64 patients, respectively. *TP* and *AM* gene expression, as assessed by RT-PCR, was significantly associated with poor prognosis in patients with epithelial ovarian cancer, respectively (4–6). There was no significant correlation between *TP* and *endostatin* gene expression ($P = 0.789$) and *AM* and *endostatin* gene expression ($P = 0.411$). Endostatin might affect the worse prognosis independently of *TP* and *AM*. However, this speculation leaves much to be investigated.

The RT-PCR method we used for determination of *endostatin* gene expression is convenient because it does not require radioisotopes or relatively large amounts of tumor tissue. Because even a small amount of samples obtained from specimens during operation is sufficient for the evaluation of *endostatin* gene expression, RT-PCR detection of *endostatin* gene expression may make it possible to identify epithelial ovarian cancer patients with poor prognoses before chemotherapy. In those patients, it is anticipated that administration of an angiogenic inhibitor like endostatin would be applied in conjunction with the conventional cytotoxic chemotherapy. Indeed, i.m. administration of the formulated *endostatin* gene inhibited both the growth of primary tumors and the development of metastatic lesions in murine models (27). Moreover, it has been revealed that rat endostatin is a potent anticancer agent in a carcinogen-induced, spontaneously arising rat breast cancer model (28).

REFERENCES

1. McGuire, W. P., Hoskins, W. J., Brady, M. F., Kucera, P. R., Partridge, E. E., Look, K. Y., Clarke-Pearson, D. L., and Davidson, M. Cyclophosphamide and cisplatin compared with paclitaxel and cisplatin in patients with stage III and stage IV ovarian cancer. *N. Engl. J. Med.*, *334*: 1–6, 1996.
2. Neijt, J. P., Engelholm, S. A., Tuxen, M. K., Sorensen, P. G., Hansen, M., Sessa, C., de Swart, C. A. M., Hirsch, F. R., Lund, B., and von Houwelingen, H. C. Exploratory Phase III study of paclitaxel and cisplatin *versus* paclitaxel and carboplatin in advanced ovarian cancer. *J. Clin. Oncol.*, *18*: 3084–3092, 2000.
3. Folkman, J. Tumor angiogenesis: therapeutic implications. *N. Engl. J. Med.*, *285*: 1182–1186, 1971.
4. Hata, K., Kamikawa, T., Arai, S., Tashiro, H., Katabuchi, H., Okamura, H., Fujiwaki, R., Miyazaki, K., and Fukumoto, M. Expression of the thymidine phosphorylase gene in epithelial ovarian cancer. *Br. J. Cancer*, *79*: 1848–1854, 1999.
5. Hata, K., Fujiwaki, R., Nakayama, K., Fukumoto, M., and Kohji, M. Expression of TP and TIE2 genes in normal ovary with corpus luteum and in ovarian cancer: correlation with ultrasound-derived peak systolic velocity. *Mol. Hum. Reprod.*, *6*: 319–323, 2000.
6. Hata, K., Takebayashi, Y., Akiba, S., Fujiwaki, R., Iida, K., Nakayama, K., Nakayama, S., Fukumoto, M., and Miyazaki, K. Expression of the adrenomedullin gene in epithelial ovarian cancer. *Mol. Hum. Reprod.*, *6*: 867–872, 2000.
7. Kruger, E. A., Duray, P. H., Tsokos, M. G., Venzon, D. J., Libutti, S. K., Dixon, S. C., Rudek, M. A., Pluda, J., Allegra, C., and Figg, W. D. Endostatin inhibits microvessel formation in the *ex vivo* rat aortic ring angiogenesis assay. *Biochem. Biophys. Res. Commun.*, *268*: 183–191, 2000.
8. O'Reilly, M. S., Boehm, T., Shing, Y., Fukai, N., Vasios, G., Lane, W. S., Flynn, E., Birkhead, J. R., Olsen, B. R., and Folkman, J. Endostatin: an endogenous inhibitor of angiogenesis and tumor growth. *Cell*, *88*: 277–285, 1997.
9. Boehm, T., Folkman, J., Browder, T., and O'Reilly, M. S. Antiangiogenic therapy of experimental cancer does not induce acquired drug resistance. *Nature (Lond.)*, *390*: 404–407, 1997.
10. Standker, L., Schrader, M., Kanse, S. M., Jurgens, M., Forssmann, W.-G., and Preissner, K. T. Isolation and characterization of the circulating form of human endostatin. *FEBS Lett.*, *420*: 129–133, 1997.
11. Sasaki, T., Fukai, N., Mann, K., Gohring, W., Olsen, B. R., and Timpl, R. Structure, function and tissue forms of the C-terminal globular domain of collagen XVIII containing the angiogenesis inhibitor endostatin. *EMBO J.*, *17*: 4249–4256, 1998.
12. Taddei, L., Chiarugi, P., Brogelli, L., Cirri, P., Magnelli, L., Raugei, G., Ziche, M., Granger, H. J., Chiarugi, V., and Ramponi, G. Inhibitory effect of full-length human endostatin on *in vitro* angiogenesis. *Biochem. Biophys. Res. Commun.*, *263*: 340–345, 1999.
13. International Federation of Gynecology and Obstetrics (FIGO). Changes in definitions of clinical staging for carcinoma of the cervix and ovary. *Am. J. Obstet. Gynecol.*, *156*: 263–264, 1987.
14. Serov, S. F., Scully, R. E., and Sobin, L. H. International Histological Classification of Tumours, no. 9: Histological Typing of Ovarian Tumours. Geneva: WHO, 1973.
15. Arai, S., Suwa, H., Mandai, M., Tashiro, H., Miyazaki, K., Okamura, H., Nomura, H., Hiai, H., and Fukumoto, M. Expression of multidrug resistance gene and localization of P-glycoprotein in human primary ovarian cancer. *Cancer Res.*, *54*: 1355–1359, 1994.
16. Saarela, J., Ylikarppa, R., Rehn, M., Purmonen, S., and Pihlajaniemi, T. Complete primary structure of two variant forms of human type XVIII collagen and tissue-specific differences in the expression of the corresponding transcripts. *Matrix Biol.*, *16*: 319–328, 1998.
17. Preston, D. L., Lubin, J. H., and Pierce, D. A. EPICURE: Risk Regression and Data Analysis Software. Seattle: HiroSoft International Corp., 1990.
18. Beale, P. J., and Friedlander, M. L. Prognostic variables in ovarian cancer. *In*: F. G. Lawton, J. P. Neijt, and K. D. Swenerton (eds.), *Epithelial Cancer of the Ovary*, pp. 96–111. London: BMJ Publishing Group, 1995.
19. Oh, S. P., Kamagata, Y., Muragaki, Y., Timmons, S., Ooshima, A., and Olsen, B. R. Isolation and sequencing of cDNAs for proteins with multiple domains of Gly-Xaa-Yaa repeats identify a distinct family of collagenous proteins. *Proc. Natl. Acad. Sci. USA*, *91*: 4229–4233, 1994.
20. Rehn, M., and Pihlajaniemi, T. $\alpha 1(\text{XVIII})$, a collagen chain with frequent interruptions in the collagenous sequence, a distinct tissue distribution, and homology with type XV collagen. *Proc. Natl. Acad. Sci. USA*, *91*: 4234–4238, 1994.
21. Hanahan, D., and Folkman, J. Patterns and emerging mechanisms of angiogenic switch during tumorigenesis. *Cell*, *86*: 353–364, 1996.
22. Wen, W., Moses, M. A., Wiederschain, D., Arbisser, J. L., and Folkman, J. The generation of endostatin is mediated by elastase. *Cancer Res.*, *59*: 6052–6056, 1999.
23. Sugarbaker, E. V., Thornthwaite, J., and Ketcham, A. S. Inhibitory effect of a primary tumor on metastasis. *In*: S. B. Day, P. L. Myers, P. Stansly, S. Garattini, and M. G. Lewis (eds.), *Cancer Research and Therapy*, pp. 227–240. New York: Raven Press, 1977.
24. Clark, W. H., Jr., Elder, D. E., Guerry, D., IV, Braitman, L. E., Trock, B. J., Schultz, D., Synnestvedt, M., and Halpern, A. C. Model predicting survival in stage I melanoma based on tumor progression. *J. Natl. Cancer Inst. (Bethesda)*, *81*: 1893–1904, 1989.
25. Prehn, R. T. The inhibition of tumor growth by tumor mass. *Cancer Res.*, *51*: 2–4, 1991.
26. O'Reilly, M., Rosenthal, R., Sage, E. H., Smith, S., Holmgren, L., Moses, M., Shing, Y., and Folkman, J. The suppression of tumor metastases by a primary tumor. *Surg. Forum (Chic.)*, *44*: 474–478, 1993.
27. Blezinger, P., Wang, J., Gondo, M., Quezada, A., Mehrens, D., French, M., Singhal, A., Sullivan, S., Rolland, A., Ralston, R., and Min, W. Systemic inhibition of tumor growth and tumor metastases by intramuscular administration of the endostatin gene. *Nat. Biotechnol.*, *17*: 343–348, 1999.
28. Perletti, G., Concar, P., Giardini, R., Marras, E., Piccinini, F., Folkman, J., and Chen, L. Antitumor activity of endostatin against carcinogen-induced rat primary mammary tumors. *Cancer Res.*, *60*: 1793–1796, 2000.

Clinical Cancer Research

Expression of the *Endostatin* Gene in Epithelial Ovarian Cancer

Kohkichi Hata, Ritsuto Fujiwaki, Kentaro Nakayama, et al.

Clin Cancer Res 2001;7:2405-2409.

Updated version Access the most recent version of this article at:
<http://clincancerres.aacrjournals.org/content/7/8/2405>

Cited articles This article cites 23 articles, 8 of which you can access for free at:
<http://clincancerres.aacrjournals.org/content/7/8/2405.full#ref-list-1>

Citing articles This article has been cited by 4 HighWire-hosted articles. Access the articles at:
<http://clincancerres.aacrjournals.org/content/7/8/2405.full#related-urls>

E-mail alerts [Sign up to receive free email-alerts](#) related to this article or journal.

Reprints and Subscriptions To order reprints of this article or to subscribe to the journal, contact the AACR Publications Department at pubs@aacr.org.

Permissions To request permission to re-use all or part of this article, use this link
<http://clincancerres.aacrjournals.org/content/7/8/2405>.
Click on "Request Permissions" which will take you to the Copyright Clearance Center's (CCC) Rightslink site.